

## How I Do It

# Approach to debridement in necrotizing fasciitis

Chin-Ho Wong, M.B.B.S., M.R.C.S. (Ed), M.Med. (Surg)<sup>a,\*</sup>,  
Andrew K.-T. Yam, M.B.B.S., M.R.C.S. (Ed), M.Med. (Surg)<sup>b</sup>,  
Agnes B.-H. Tan, M.B.B.S., F.R.C.S., F.A.M.S.<sup>b</sup>,  
Colin Song, M.B.B.Ch., F.R.C.S., F.A.M.S.<sup>a</sup>

<sup>a</sup>Department of Plastic Reconstructive and Aesthetic Surgery, Singapore General Hospital, Outram Road, Singapore 169608; <sup>b</sup>Department of Hand Surgery, Singapore General Hospital, Singapore

### KEYWORDS:

Necrotizing soft tissue  
infection;  
Aggressive;  
Control;  
Mortality;  
Morbidity;  
Systematic

**Abstract.** Aggressive debridement is a cornerstone intervention in necrotizing fasciitis. Our approach consists of 4 steps: (1) confirming the diagnosis and isolate the causative organism; (2) defining the extent of fasciitis; (3) surgical excision; and (4) post-excision wound care. The extent of the infection is defined by probing the wound bluntly. Systematic excision follows. Fascial excision must be complete and uncompromising with the full extent of the involved wound laid open. We classify the infected skin into zones 1, 2, and 3. Zone 1 is necrotic tissue. Zone 2 is infected but potentially salvageable soft tissue, and zone 3 is non-infected skin. Zone 1 is completely excised. Zone 2 is meticulously assessed and cut back as necessary to remove nonviable tissue while maximally preserving salvageable tissue. Zone 3 is left alone. The aim of surgical debridement is to remove all infected tissue in a single operation. This halts the progression of the fasciitis and minimizes unnecessary returns to the operating room.

© 2008 Elsevier Inc. All rights reserved.

In the spectrum of soft tissue infections, necrotizing fasciitis is perhaps the most fulminant and deadliest, with the reported mortality rate ranging from 6% to 76%.<sup>1</sup> It is unequivocal that delay in diagnosis and surgical debridement increases morbidity and mortality.<sup>1–12</sup> While it is universally accepted that aggressive debridement is crucial to control this fulminant infection, a detailed description of how to perform this often massive debridement is lacking in the literature. Furthermore, because of its rarity, most surgeons will probably encounter only a handful of cases in their career and therefore familiarity with this disease will seldom be achieved by most. Often, the surgeon adopts surgical approaches used for more common infections such

as abscesses. This lack of a focused, tactical approach when confronting this severe infection often results in suboptimal debridement and failure to rapidly get above the infection and halt its progression. This report describes our surgical approach to debridement in necrotizing fasciitis, stressing the concept of *radical excisional debridement* as the definitive action to halt the progression of necrotizing fasciitis. While this description is aimed at the first debridement, these principles and techniques are also applicable if subsequent debridements are necessary.

## Classification of Skin and Subcutaneous Tissue Involvement

Skin and subcutaneous infection commonly results from vertical spread from the primary site of pathology, ie, the

\* Corresponding author. Tel.: +65 6321 4686; fax: +65 6220 9340.

E-mail address: [wchinho@hotmail.com](mailto:wchinho@hotmail.com)

Manuscript received April 12, 2007; revised manuscript July 26, 2007

deep fascia. Fascial edema and inflammatory thrombosis (thromboangiitis obliterans) occlude the cutaneous perforators that run through the deep fascia to supply the skin. The resulting ischemia and necrosis promote the spread of infection. All skin and subcutaneous tissue located over the involved fascia is therefore at risk. Skin necrosis spreads in a centrifugal manner away from the center of the fasciitis, in tandem with its advancing edge. The skin and subcutaneous tissue at the advancing edge of the fasciitis survive on collateral circulation from the dermal and the subdermal plexus coming from the surrounding unaffected tissue, and may survive surgical excision of the underlying infected fascia.

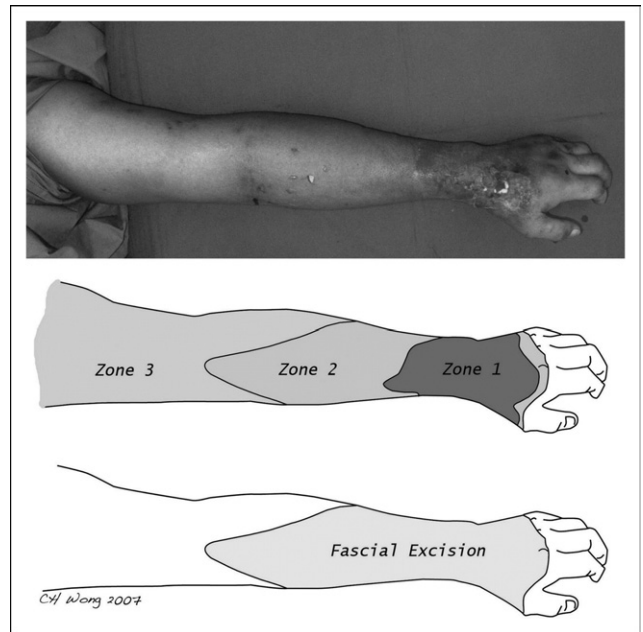
To facilitate decision-making during skin excision, we classified the skin and subcutaneous component into 3 surgical zones: zones 1, 2, and 3. Zone 1 is the area of nonviable skin at the epicenter of infection. It demonstrates the classic late signs of necrotizing fasciitis: hemorrhagic bullae, dermal hemorrhage, fixed staining, and frank dermal gangrene. Adjacent and surrounding this area, usually extending in the direction of advancing infection, is zone 2. This transitional area can potentially be salvaged if the infection is rapidly controlled. The signs of early necrotizing fasciitis are seen in this area: warm (hot) skin, intense erythema, small serous bullae, and woody induration signifying underlying fascial involvement. Zone 3 is located beyond zone 2 and is healthy uninfected tissue (Figure 1). The boundary between zones 2 and 3 often marks the limit of the underlying fasciitis. Clinical assessment of skin viability is important in deciding on the extent of skin excision and will be discussed later.

## Aims of the First Debridement in Necrotizing Fasciitis

Four areas must be addressed at the first debridement. These are (1) confirming the diagnosis of necrotizing fasciitis and isolating the causative organism; (2) delineating the extent of the infection; (3) complete surgical excision of infected tissue; and (4) post-excision wound care.

### Confirming the diagnosis and organism

A clinical diagnosis of necrotizing fasciitis can be made based on findings at wound exploration. The following features are seen in necrotizing fasciitis: grayish necrotic deep fascia, a lack of resistance of normally adherent muscular fascia to blunt finger dissection, lack of bleeding of the fascia, and the presence of foul-smelling “dishwater” pus.<sup>2</sup> The muscle itself is not involved. Histology may confirm the diagnosis and is particularly helpful in early necrotizing fasciitis where clinical findings may sometimes be equivocal.<sup>13,14</sup> The histological specimen should be a full thickness



**Figure 1** (Top) Clinical photograph of the involved hand. (Middle) Classification of the involved skin and subcutaneous tissue into zones 1, 2, and 3 based on skin manifestations of necrotizing fasciitis. Zone 1 is the area of obvious skin necrosis. This area is characterized by skin gangrene, fixed discoloration, and hemorrhagic bullae. Zone 1 will be completely excised as it is clear that it is nonviable and heavily infected. Zone 2 is characterized by skin manifestations of early necrotizing fasciitis. This area is characterized by red warm skin and exquisite tenderness. Induration may be felt in this area and small serous bullae may be seen. Particularly telling is “woody hard” quality of the skin that can occasionally be appreciated here. Zone 2 is the area at risk and with some areas potentially salvageable with antimicrobial therapy if its microcirculation is still patent. This area should be carefully assessed, and progressively cut back to evaluate the tissue quality and for bleeding. Zone 3 is normal skin that is clinically not infected. (Bottom) The extent of fascial involvement. This area is defined by probing the wound at the deep fascia level and any area that skin and subcutaneous tissue can be lifted off the muscle is involved. Complete excision of the involved fascia is mandatory.

tissue specimen incorporating skin, subcutaneous tissue, deep fascia, and a piece of muscle.

### Delineating the extent of infection

Clinically, the extent of infection is predicted by the limit of tenderness to palpation. This usually occurs somewhere just beyond the interface of zones 2 and 3 in our classification. Therefore, an extensile incision is planned, ending distally and proximally well into zone 3. If the infection is in a limb and appears to have spread circumferentially, it may be necessary to plan 2 separate incisions on opposite surfaces to access the entire fascia. At the margin of zone 2 and in zone 3, blunt finger dissection to unyielding fascia confirms the extent. This establishes the perimeter within which all fascia must be excised.

## Complete surgical excision

Once the perimeter is established, all fascia within is excised completely. We advocate taking a 5- to 10-mm margin of healthy fascia in zone 3 as well. This "firebreak" impedes further advancement of the infection beyond the margin of excision. All necrotic skin and subcutaneous tissue in zone 1 is excised, along with any tissue of questionably viability in zone 2.

## Post-excision wound care

The extensive surgical debridement will result in large raw wounds. Patients, particularly those who are coagulopathic from sepsis, are at risk of postoperative hemorrhage. In addition, immunocompromised patients are at risk of secondary infection. Wound care aims to minimize both of these risks. Meticulous hemostasis is essential, with the tourniquet (if applied) deflated. The wound should be covered with non-adherent dressings such as Urgotul (Urgo Limited, Leicestershire, UK) or tulle gras. An antibiotic cream (eg, Mupirocin) or active silver dressings (eg, Urgotul SSD, Aquacel Ag; ConvaTec, NJ, USA) may be added. A firm, bulky cotton wool pressure dressing is applied and removed only after 24 hours to inspect the wound. Further dressing changes should be dictated by the condition of the debrided wound. While the use of topical negative pressure dressings is increasingly popular for large wounds, we do not recommend their use immediately after the first debridement, as there is an increased risk of hemorrhage from the raw area. They may be used effectively for subsequent dressings.

## Surgical Technique

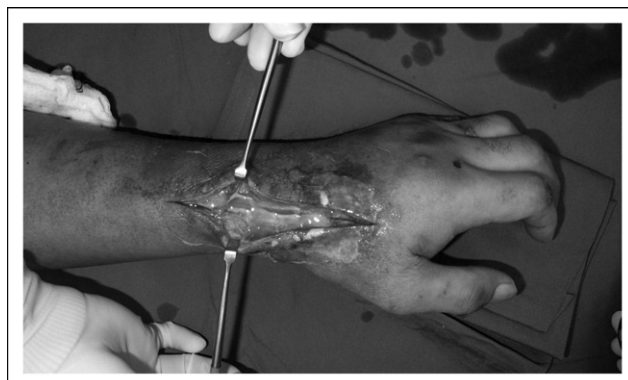The operation should be performed under general anesthesia. In the limbs, a tourniquet should be used to reduce blood loss. A bloodless field also aids dissection by making plane identification easier. Prior to incision, skin markings to delineate zones 1, 2, and 3 are as described. A curvilinear skin incision is also marked running through the center of the infected area, extending through the entire area from normal skin distally to normal skin proximally.

The incision should start at zone 1. A full-thickness incision down to muscle is made. The deep fascia is identified as the layer of tissue lying just above the muscles. A clinical diagnosis of necrotizing fasciitis is made based on features described above. At this juncture, 2 tissue specimens should be sent for investigation: 1 for aerobic and anaerobic cultures and 1 for histology (frozen sections and hematoxylin and eosin stains). Then, in order to determine the extent of involvement, the surgeon probes his or her finger along the deep fascia. Any area where the skin and subcutaneous tissue can be lifted off easily is involved.<sup>15</sup> The incision is then extended proximally in a longitudinal

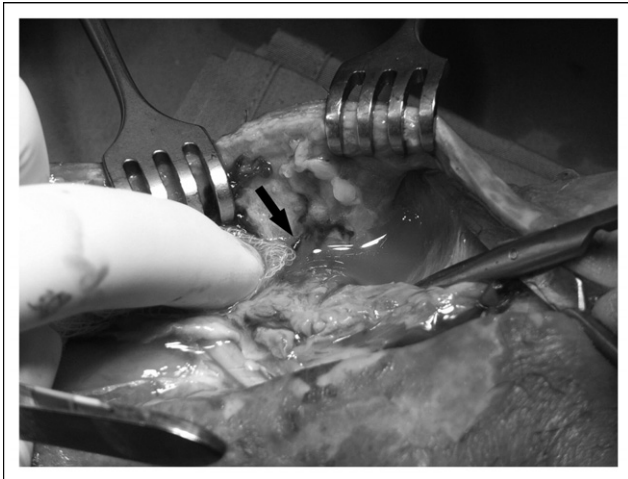
manner until healthy fascia adherent to the overlying subcutaneous tissue and underlying muscle is encountered. The perimeter is now established and the wound is then laid open to expose the entire infected bed.

Radical fasciectomy is then performed. The fascia is excised sharply, exposing the underlying muscles and tendons, indicating that the fascia has been completely removed. The periphery of the wound is checked by tugging the deep fascia with a rongeur or a hemostat. Healthy fascia has a glistening appearance and is tough and unyielding when tugged. Infected fascia on the other hand is dull, soft, and friable. This should be further cut back until healthy fascia is seen. Skin excision then follows. Skin in zone 1 is necrotic and the entire zone should be excised. Zone 2 should be carefully assessed for viability. If dermal bleeding is poor, indicating occlusion of the microcirculation due to necrotizing angitis-type pathology, this skin is not salvageable and should be excised until healthy dermal bleeding is encountered. The subcutaneous tissue also should be examined for signs of tissue viability. Calcifications or liquefaction of the subcutaneous fat and thrombosis of the subdermal venules indicates impending tissue demise and should be excised. We find it useful to observe the microcirculation in the subdermal or subcutaneous vessels. Patent arterioles and venules are a sign of tissue viability and can be safely preserved. These can be observed by lifting the skin flap and examining these vessels through the deep aspect of the subcutaneous tissue. The presence of thrombosed, phlebotic vein should be traced proximally until a patent segment is noted. All tissue surrounding the thrombosed vein is compromised and should be excised with the vein. The tourniquet should be deflated upon completion of debridement and the wound checked to confirm tissue viability. Compromised tissue should be further cut back as necessary.

Finally, the tourniquet is deflated and meticulous hemostasis is achieved by cautery. The wound is washed with copious irrigation and dressed as described earlier. The wound should be inspected again by the same surgeon within 24 hours to assess tissue viability and for progression of the infection.



**Figure 2** The clinical diagnosis of necrotizing fasciitis was confirmed intraoperatively by a deep incision down to the deep fascia.



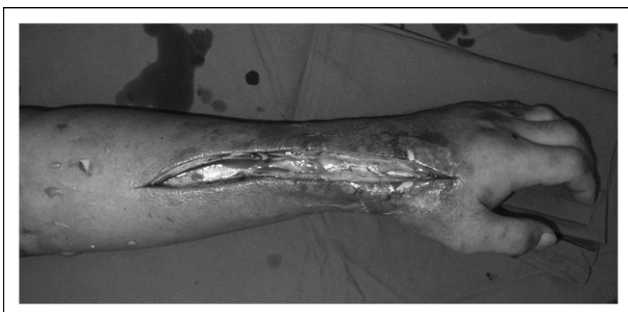
**Figure 3** Foul-smelling, turbid “dishwater” pus seen in necrotizing fasciitis. This photograph also shows a thrombosed cutaneous perforator supplying the skin and subcutaneous tissue (arrow). This is a useful diagnostic marker of tissue viability. The skin and subcutaneous tissue around such a thrombosed vessel is often heavily infected and nonviable. These tissues surrounding the thrombosed vessel should therefore be excised.

**Illustrative Case**

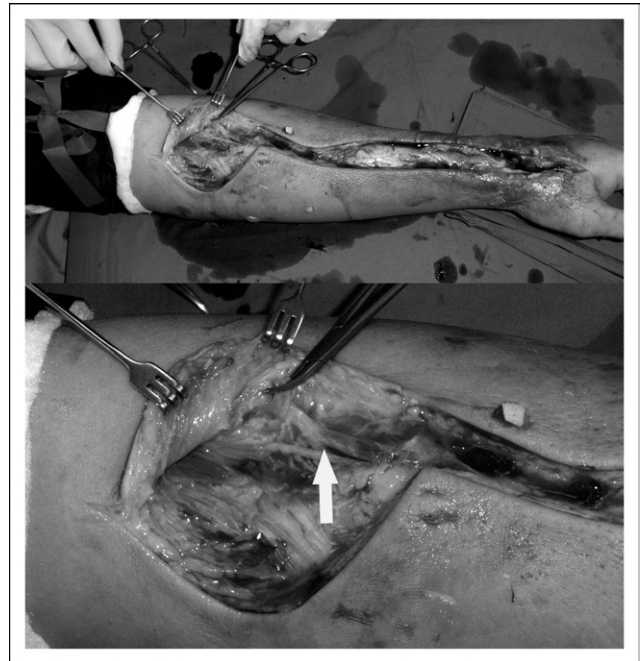
A 53-year-old man with diabetes mellitus and chronic renal failure was admitted for congestive heart failure. He developed sepsis and collapsed in the ward. He was intubated and admitted to the intensive care unit. Left forearm and hand swelling, redness, and discoloration were noted and a clinical diagnosis of necrotizing fasciitis was made and an emergency wound exploration was performed. Figures 1 through 7 showed the operative finding and progress of the debridement.

**Comments**

The technique we have described is based on our clinical experience in managing these cases with a clear and focused aim of removing all infected tissue at the first operation. Using this technique, we have managed to control the infection in a single operation in 15 of 21 cases. Our guiding principles when devising these strategies are the following:

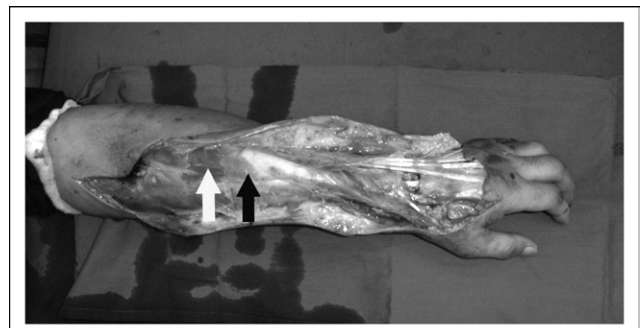


**Figure 4** The incision was extended into zone 2.

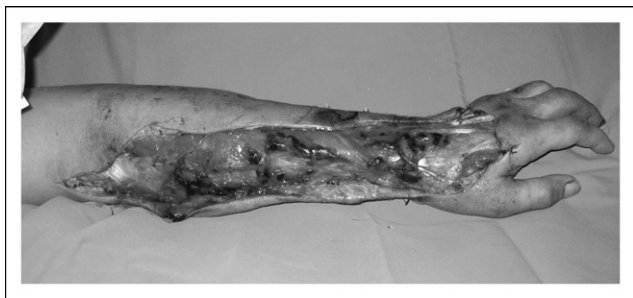

**Figure 5** (Top) The incision was further extended until zone 3 was reached. Generally, the incision should stop only when normal fascia is seen. The cephalic vein and its tributaries were thrombosed and heavily infected. The vein was thus traced proximally until a patent segment was seen (arrow) and the vein was ligated at about 3 cm proximal to the thrombosed area. Thrombosis of subcutaneous veins is a useful diagnostic clue of the extent of necrotizing soft tissue infection. All soft tissue around the phlebotic vein must be excised.

(1) to control the infection by surgically removing the primary site of pathology, ie, the deep fascia; and (2) to determine and maximally preserve skin coverage without compromising our aim of removing all infected tissue. Fasciectomy should therefore be aggressive and uncompromising. Skin excision is a little more difficult and requires a degree of clinical judgement to balance the need to remove devitalized tissue versus the desire to maximally preserve potentially salvageable tissue. Failure to remove all devitalized skin is the main reason for multiple returns to the



**Figure 6** The infected fascia must be completely excised leaving only muscle and tendon in the bed of the wound (white arrow). Any fascia left on the wound bed must be excised (black arrow).



**Figure 7** Wound at the first inspection 24 hours later. One can remove all infected tissue with aggressive debridement and avoid unnecessary return to the operating room for repeat debridement.

operating room.<sup>2</sup> To facilitate rapid debridement and to focus the assessment of skin viability to the area where careful evaluation is needed most, we have devised a concept of zoning the skin over the involved site.

Proponents of a more conservative approach to debridement argue that it is difficult to assess tissue viability in an acutely infected wound. In the interest of maximally preserving soft tissue coverage over vital structures, it is prudent to be more conservative and return in 24 to 48 hours to reassess the wound. However, this approach is not appropriate and may be dangerous when applied in the context of necrotizing fasciitis.<sup>3,5–8,14</sup> Such patients are severely septic and complete removal of all infected tissue is the only way to rapidly reverse the sepsis. Furthermore, failure to remove all infection may allow it to progress further, resulting in even more tissue loss.

We use non-occlusive dressings with large amounts of gauze as a secondary dressing because these are highly exudative wounds. A tight compression-type bandaging should be applied for hemostasis. Negative pressure therapy (V.A.C. dressings; Kinetics Concepts, Inc, San Antonio, TX) should not be used after the first surgical debridement as the suction may increase postoperative bleeding. However, V.A.C. is a valuable wound management adjunct in necrotizing fasciitis and can be applied if the wound is clean after the first wound inspection, while waiting for the patient's general condition to improve prior to wound closure with skin grafts or flaps. The use of hyperbaric oxygen therapy has been demonstrated to decrease mortality and wound morbidity in recent retrospective studies and should be used when a facility is available.<sup>14,16–19</sup>

Not all patients will recover with a single debridement. Immunocompromised patients with poor wound healing potential, such as patients with diabetes mellitus and renal failure, are particularly difficult to manage. In such patients, even with a successful initial debridement, secondary wound infection may occur due to poor healing and decreased tissue perfusion. Peripheral vasoconstriction caused by inotropic agents (such as epinephrine and norepinephrine) for hypotension associated with sepsis may compound this problem. Repeat debridement may be needed, and treatment is generally supportive while waiting for the systemic conditions to improve. Amputation also may be necessary in some cases. Despite this, we strongly stress the impor-

tance of a thorough and systematic initial debridement in these patients as a life-saving procedure. This immediately halts progression of the necrotizing fasciitis, allowing sepsis and the systemic inflammatory response to reverse rapidly.

Wound closure should be optimally timed to ensure success. In general one should refrain from rushing to close the wound. The wound must demonstrate that the healing phase has firmly set in prior to closure, regardless of whether secondary suture or skin grafts or flaps are to be used. This is done by observing the ability of the wound to form granulation tissue. This process can somewhat be promoted by the use of the V.A.C. dressing. We call this a "trial of V.A.C. therapy"; a wound with abundant healthy granulation tissue after a 3- to 5-day course of V.A.C. therapy signals an opportune time for closure.

## Conclusion

Debridement for necrotizing fasciitis is not a "slash and burn"-type surgery. The concepts and techniques described here are common knowledge to many experienced surgeons. What is more important perhaps is that there should be a fundamental shift in the surgeon's mindset when performing this procedure. The surgeon should not perform the debridement expecting to return to find more necrotic tissue and repeat the process. Instead, the aim should be to remove all infected tissue in a single operation. Patience, precision, and meticulous technique improve the outcome and make a huge difference to the patient.

## Acknowledgment

The authors would like to acknowledge all physicians and surgeons who have given us the privilege of participating in the care of their patients with necrotizing fasciitis and who have taught us so much. We also would like to thank Jane Wong for her help with illustrations in this article.

## References

1. McHenry CR, Piotrowski JJ, Petrinic D, et al. Determinants of mortality in necrotizing soft tissue infections. *Ann Surg* 1995;221:558–63.
2. Wong CH, Chang HC, Pasupathy S, et al. Necrotizing fasciitis: clinical presentation, microbiology and determinants of mortality. *J Bone Joint Surg (A)* 2003;85:1454–60.
3. Voros D, Pissiotis C, Georgantas D, et al. Role of early and aggressive surgery in the treatment of severe necrotizing soft tissue infections. *Br J Surg* 1993;80:1190–1.
4. Rea WJ, Wyrick WJ. Necrotizing fasciitis. *Ann Surg* 1970;72:957–64.
5. Masjeski JA, Alexander JW. Early diagnosis, nutritional support and immediate extensive debridement improve survival in necrotizing fasciitis. *Am J Surg* 1983;145:781–7.
6. Bilton BD, Zibari GB, McMillan RW, et al. Aggressive surgical management of necrotizing fasciitis serves to decrease mortality: a retrospective study. *Am Surg* 1998;64:397–400.

7. Green RJ, Dafoe DC, Raffin TA. Necrotizing fasciitis. *Chest* 1996;110:219–9.
8. Majeski J, Majeski E. Necrotizing fasciitis: improved survival with early recognition by tissue biopsy and aggressive surgical treatment. *South Med J* 1997;90:1065–8.
9. Wang K-C, Shih C-H. Necrotizing fasciitis of the extremities. *J Trauma* 1992;32:259–64.
10. Freischlag JA, Ajalat G, Busuttill RW. Treatment of necrotizing soft tissue infections: the need for a new approach. *Am J Surg* 1985;149:751–5.
11. Ault MJ, Geiderman J, Sokolov R. Rapid identification of group A streptococcus as the cause of necrotizing fasciitis. *Ann Emerg Med* 1996;28:227–30.
12. Elliot DC, Kufera JA, Myers RA. Necrotizing soft tissue infections: risk factors for mortality and strategies for management. *Ann Surg* 1996;224:672–83.
13. Stamenkovic I, Lew PD. Early recognition of potentially fatal necrotizing fasciitis: the use of frozen section biopsy. *N Engl J Med* 1984;310:1689–93.
14. Wong CH, Wang YS. The diagnosis of necrotizing fasciitis. *Curr Opin Infect Dis* 2005;18:101–6.
15. Andreasen TJ, Green SD, Childers BJ. Massive soft-tissue injury: diagnosis and management of necrotizing fasciitis and purpura fulminans. *Plast Reconstr Surg* 2001;107:1025–35.
16. Korhonen K, Kuttilla K, Niinikoski J. Tissue gas tensions in patients with necrotizing fasciitis and healthy controls during treatment with hyperbaric oxygen: a clinical study. *Eur J Surg* 2000;166:530–4.
17. Riseman JA, Zamboni WA, Curtis A, et al. Hyperbaric oxygen therapy for necrotizing fasciitis reduces mortality and the need for debridements. *Surgery* 1990;108:847–50.
18. Stevens DL, Bryant AE, Adams K, et al. Evaluation of therapy with hyperbaric oxygen for experimental infection with *Clostridium perfringens*. *Clin Infect Dis* 1993;17:231–7.
19. Wilkinson D, Doolette D. Hyperbaric oxygen treatment and survival from necrotizing soft tissue infection. *Arch Surg* 2004;139:1339–45.