

Surgical Anatomy of the Middle Premasseter Space and Its Application in Sub-SMAS Face Lift Surgery

Bryan C. Mendelson,
F.R.C.S.E., F.R.A.C.S., F.A.C.S.
Chin-Ho Wong, M.R.C.S.(Ed.),
F.A.M.S.(Plast. Surg)

Toorak, Victoria, Australia;
and Singapore



Background: The premasseter space is a recognized, sub-superficial musculoaponeurotic system (SMAS) soft-tissue space overlying the lower masseter immediately anterior to the parotid. The performance, safety, and effectiveness of composite face lifts are enhanced when the space is used. This has drawn attention to the need for better understanding of the premasseter anatomy above the space.

Methods: The anatomy of the upper premasseter region was investigated in 20 fresh cadaver dissections as well as intraoperatively in hundreds of composite face lifts.

Results: A small, transverse, rectangular soft-tissue space overlies the upper masseter and was named the middle premasseter space. The space (transverse width, 25 to 28 mm; vertical width, 10 mm) is separated from the originally described (lower) premasseter space by a double membrane. It is a safe space between the upper and lower buccal trunks of the facial nerve, which are immediately outside the space and separated from it by the respective upper and lower boundary membranes. The parotid duct immediately beneath the floor of the space usually underlies the upper boundary membrane.

Conclusions: The middle premasseter space is significant, as it is the center of the key anatomy immediately cephalad to the lower premasseter space. When used in composite face lifts, the space provides predictable sub-SMAS dissection between the buccal trunks of the facial nerve to the mobile area beyond the anterior border of the masseter where the SMAS overlies the buccal fat pad. (*Plast. Reconstr. Surg.* 132: 57, 2013.)

The concentric layered structure of the facial soft tissues provides the basis for its function. To enable the movement of facial expression, the superficial fascia layers have specialized adaptations in the mobile anterior face, whereas the structures involved in mastication are beneath the deep fascia of the lateral face.^{1,2} Consistent with the complexity of its function, the sub-superficial musculoaponeurotic system (SMAS) interface between the superficial and deep fascial layers is unique in the body. This plane has both soft-tissue spaces and retaining ligaments, each with contrasting functions. The spaces allow for the mobility of the overlying superficial fascia, while the ligaments provide for its stability. The relative proportion of spaces and ligaments, as well as their distribution, varies according to the function

of the particular region of the face.³⁻⁵ The retaining ligaments are most densely arranged where there is less movement, such as over the lower body of the zygoma; in contrast, spaces predominate where movement is greater, such as over the lower masseter. The spaces and ligaments are integral

Disclosure: *The authors have no financial interest to declare in relation to the content of this article. No external funding was received.*

Supplemental digital content is available for this article. A direct URL citation appears in the text; simply type the URL address into any Web browser to access this content. A clickable link to the material is provided in the HTML text of this article on the *Journal's* Web site (www.PRSJournal.com).

From the Center for Facial Plastic Surgery and W Aesthetic Plastic Surgery.

Received for publication December 21, 2012; accepted January 14, 2013.

Copyright © 2013 by the American Society of Plastic Surgeons

DOI: 10.1097/PRS.0b013e3182910b70

to the pathogenesis of the changes of facial aging. Laxity becomes more pronounced in the areas of movement, where there are fewer ligaments, such as in the anterior face.

The soft-tissue spaces of the face have certain characteristics, including (1) defined membranous boundaries, (2) an absence of vital structures within or crossing the spaces, and (3) retaining ligaments and vital neurovascular structures located within the boundaries (between spaces). These anatomic characteristics allow the spaces to be utilized for easy and safe surgical access to various parts of the face and are the reason why certain areas beneath the SMAS can be dissected virtually bloodlessly.⁴ The recognized sub-SMAS soft-tissue spaces in the face are the temporal, pre-septal, prezygomatic, and premasseter spaces.⁶⁻⁹

The recently described premasseter space is significant for several reasons. The aging changes that occur in the lower face, particularly the jowl, are explained by the laxity that develops in the roof and anterior boundary of the space. Then, in the correction of this laxity, the large “avascular” area of the premasseter space provides safe surgical access to the anterior lower face beyond the space.⁹

The area overlying the masseter above the premasseter space has previously been described, in cautionary tones for the surgeon, as an “area of important anatomy” because of the vital structures located here. Most significant are the zygomatic and buccal trunks of the facial nerve with their intercommunicating branches, as well as the parotid

duct and the masseteric-cutaneous ligaments. During operations within this “area of important anatomy,” it had been noted that it contains a distinct, small avascular cleavage plane, which has been cautiously utilized. It was thought that if this plane represented a true soft-tissue space similar to the premasseter space below, it could offer the potential to provide an anatomically safe plane of access to the anterior face in this area considered “high risk.” This definitive study of the “area of important anatomy” was undertaken with specific focus on its structure, extent, and anatomic relations, as well as its potential use for access to the anterior face.

MATERIALS AND METHODS

Detailed dissection (using loupe magnification) was performed on 20 fresh hemifacial cadaver specimens ranging in age from 42 to 78 years. In four specimens, methylene blue dye was injected directly into the space to help define its exact boundaries. Measurements were recorded and photographic documentation was taken of all the dissections. This information was supplemented by detailed observations of the intraoperative anatomy during several hundred sub-SMAS composite rhytidectomy procedures (performed by the senior author, B.C.M.).

RESULTS

In the area above the premasseter space, there is a second soft-tissue space (Fig. 1). Although

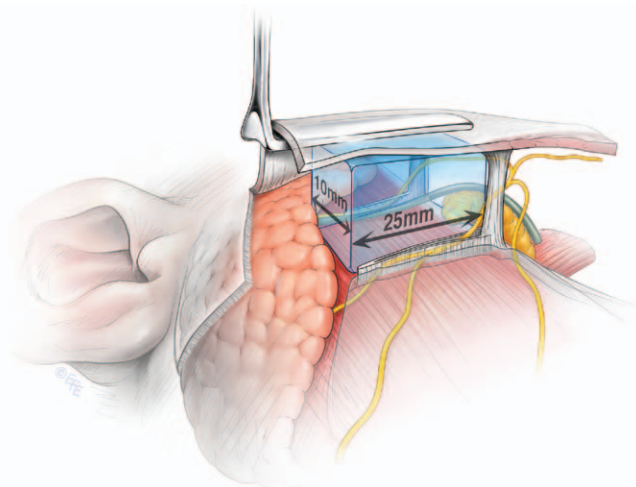


Fig. 1. The middle premasseter space is located within the concavity of the parotid overlying the anterior masseter, above the lower space. The upper and lower buccal trunks of the facial nerve course outside the space within the upper and lower boundaries of the space. The masseteric process of the buccal fat pad is the only content and is variable. (Reprinted with permission from Dr. Levent Efe.)

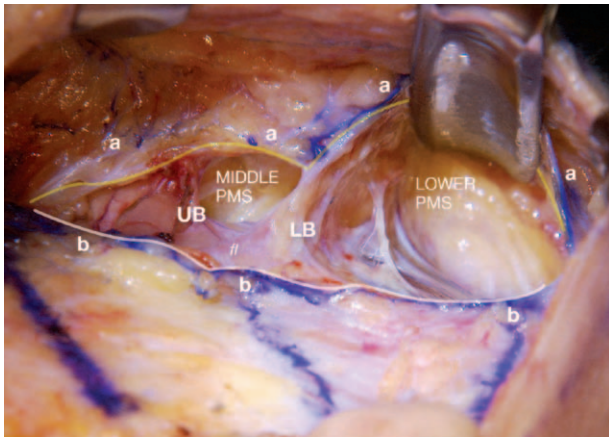


Fig. 2. Surgical dissection of the right side of the face with retractor in the lower premasseter space (PMS). The medial edge of the SMAS incision is indicated by *aaa* and the lateral edge by *bbb*. UB, upper boundary; LB, lower boundary; fl, floor of the middle premasseter space.

compact, the second premasseter space is similar to the lower space in that it is an avascular cleavage plane between the masseter fascia floor and the overlying SMAS, and it has distinct boundaries (Fig. 2). According to the definition, this localized area of cleavage plane can be considered a true facial soft-tissue space.⁵ In addition, when the dissections were extended further cephalad into the upper part of the “area of important anatomy,” which is immediately inferior to the prezygomatic space, a third, still smaller area of avascular cleavage plane was found over the upper masseter. The presence of three spaces overlying the masseter has necessitated a change of nomenclature, which for clarity of description is introduced here.

The originally described premasseter space should now be considered the lower premasseter space. The space above it, the focus of this study, is the middle premasseter space, while the smallest space just above is considered the upper premasseter space.

Middle Premasseter Space

The middle premasseter space is rectangular in shape, with its posterior boundary located approximately 40 mm forward of the upper tragus and its anterior boundary at the anterior border of the masseter. Separating the middle space from the lower premasseter space is a shared boundary, formed by the lining membrane of each space.

Floor

The rectangular floor of the middle premasseter space, measuring 25 to 28 mm × 10 mm, is formed by the masseter fascia that directly overlies and is

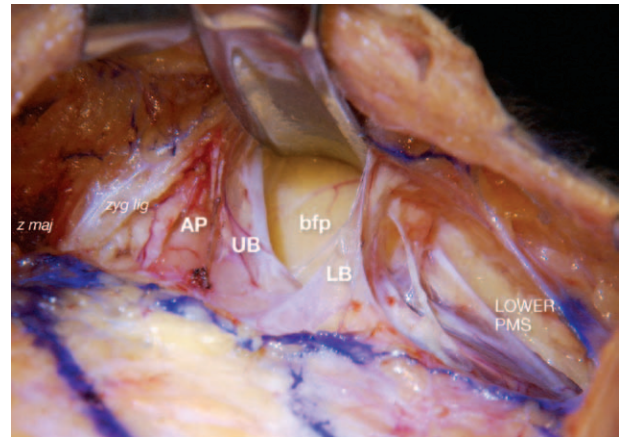


Fig. 3. Retractor elevating the roof of the middle premasseter space (PMS). There has been further dissection of the upper boundary (UB) and lower boundary (LB) membranes. Overlying the upper masseter cephalad to the middle space is the accessory lobe of the parotid (AP). Above that are the zygomaticus major (*z maj*) and zygomatic ligaments (*zyg lig*).

adherent to the masseter (Fig. 3). The masseter here is muscular posteriorly but aponeurotic in its anterior part. The accessory lobe of the parotid overlies the surface of the masseter immediately cephalad to the space. The size of the accessory lobe varies. When it is large, the lower part of the accessory lobe tends to extend inferiorly beneath the floor of the space, so that the parotid parenchyma is interposed between the membranous floor and the masseter. There are no structures passing through the floor of the middle premasseter space, although the membranous floor may bulge into the space when it is not tightly adhered to the masseter.

Posterior Border

The posterior extent of the middle premasseter space, similar to that of the lower space, is at the anterior border of the parotid, between 35 and 40 mm anterior to the tragus. The parotid parenchyma is covered by the platysma-auricular fascia. As described by Furnas,¹⁰ the platysma-auricular fascia is formed by the fusion of the preauricular SMAS with the underlying parotid capsule. It is a broad area of retaining ligament in the same plane as the platysma (the muscular part of the SMAS) in the interval between the tragal cartilage and the posterior border of the platysma. Given that the platysma-auricular fascia is fused with the parotid capsules, there is no sub-SMAS space under the platysma-auricular fascia.

Roof

The roof is formed by the SMAS and its shape reflects the shape of the floor. The roof is not

fixed because it overlies the space, in contrast to the fixed platysma-auricular fascia immediately behind the space. The platysma, which is within the SMAS roof of the lower premasseter space, does not extend sufficiently cephalad to be in the roof of the middle space. It extends only to the level of the lower key masseteric ligament, through which the upper edge of the platysma is attached to the masseter fascia. There are no facial nerve branches within the roof.

Lower Border

The lower border of the middle premasseter space is formed by the membrane of the floor as it sweeps off the floor and continues up to form the septum of the lower border and then continues to line the roof (Fig. 4). Separating this boundary membrane from the lower premasseter space is a small trapezoid-shaped interval between two membranes.

The interval is narrow posteriorly (barely 2 mm apart) and wider anteriorly (about 8 mm). The lower boundary of the middle premasseter space forms the upper membrane of the interval, whereas the lower is the upper membranous boundary of the lower premasseter space (Fig. 5).

The lower buccal trunk of the facial nerve, after it has crossed obliquely under the floor of the lower premasseter space, gains access into this interval (between the two boundary membranes). Once in the interval, the nerve changes direction to run transversely, initially at the level of the

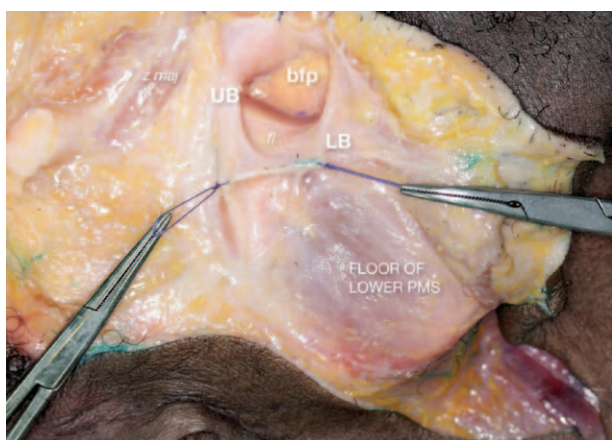


Fig. 4. Middle premasseter space (PMS) with the roof opened reveals the continuous membrane lining the space and the continuity of the space beyond the anterior edge of masseter through its open anterior boundary. The buccal fat pad (*bfp*) is seen through the anterior boundary. The membranous floor of the lower premasseter space remains. *UB*, upper boundary; *LB*, lower boundary; *fl*, floor of the middle premasseter space; *z maj*, zygomaticus major.

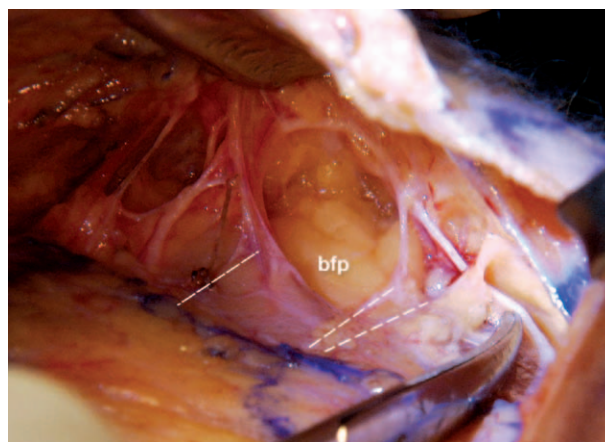


Fig. 5. The membranous walls of the upper boundary and lower boundary have been removed to reveal the nerves behind the boundary membrane. The *dashed line* indicates where the upper and lower boundary membranes attach to the floor. The *double dashed lines* represent the two membranes bounding the interval in the lower border.

floor until it approaches the anterior edge of the masseter, where it rises off the floor to reach the underside of the SMAS. At this more superficial level, the nerve passes immediately on the upper surface of the lower key masseteric ligament; after giving off connecting branches to both the upper buccal trunk and the mandibular branch, it continues forward superficial to the buccal space to the muscles of the lip.

Upper Border

The upper border is similar to the lower border, in that it is formed by the reflection of the floor membrane as it continues around to the ceiling of the space, although the upper border membrane is firmer, since it is reinforced at its anterior edge by the strong upper key masseteric ligament (Fig. 4). The upper buccal trunk of the facial nerve is directly behind the upper border immediately outside the space. The nerve exits the anterior border of the parotid posterior to and about 3 to 5 mm cephalad to the level of the upper boundary of the middle space and the parotid duct (Fig. 6).

The upper buccal trunk is on a level immediately superficial to that of the parotid duct, which it gently crosses from above, to first overlie the duct continuing forward on its outer surface, and eventually it becomes inferior to the duct. As the nerve approaches the anterior border of the masseter, it rises up behind the upper boundary membrane to be just under the superficial fascia roof at the location of the upper key masseteric ligament. The upper buccal trunk crosses the ligament on its inferior aspect, after which it shares connections

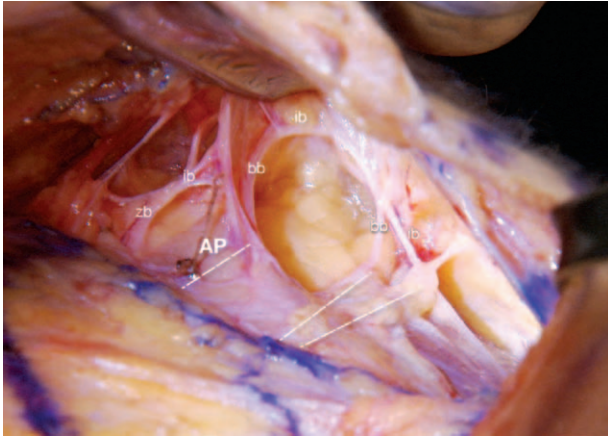

Fig. 6. The middle premasseter space is located in between the upper and lower buccal nerve branches of facial nerve (*bb*). Their interconnecting branch (*ib*) is forward of the space over the roof of the buccal space. Cephalad to the space is the accessory lobe of parotid (*AP*), and further cephalad is the zygomatic branch of the facial nerve (*zb*), with an interconnecting branch to the upper buccal nerve branch.

above with branches of the zygomatic and below with the communicating branch off the lower buccal trunk, before continuing forward into the anterior face on the underside of the SMAS.

Anterior Border

All four aspects of the lining membrane from the roof, the floor, and the upper and lower boundaries lead directly to the anterior opening between the pair of pillar-like, key masseteric ligaments, through to the anterior face. When looked at from behind, the anterior boundary is not membranous; rather, the space continues forward over the buccal fat medial to the anterior border of the masseter. The fat pad usually bulges upward, pushing up its transparent covering membrane.

The hanging underside of the SMAS is also seen through the opening. When this is lifted, the transversely oriented interconnecting nerve linking the two buccal trunks is clearly visualized where it directly overlies the membranous covering of the buccal fat pad, which is forward of the middle premasseter space (Fig. 6).

The Parotid Duct and Middle Premasseter Space

The parotid duct continues from its origin in the parotid directly on the surface of the masseter, coursing forward and slightly downward to where it directly underlies the membranous upper boundary of the middle space (Fig. 7). The duct maintains this level directly outside the space at all times. Where the upper buccal nerve trunk comes to overlie the duct, it is separated from direct

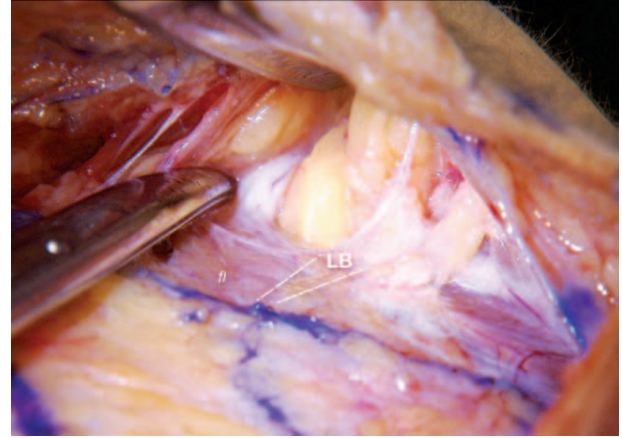


Fig. 7. The parotid duct (at the tip of the scissor) crosses the space under the membranous floor (*fl*), usually under or near the upper boundary. The parotid duct leaves this level at the anterior border of the masseter and then crosses over the membranous roof of the buccal space. *LB*, lower boundary.

contact with the duct by a thin opaque layer of fascia. The duct continues forward to the upper key masseteric ligament and passes around it on its inferior aspect, near the masseteric origin of the ligament at its base. After leaving its relation with the anterior boundary of the space, the duct takes a transverse and slightly upward course over the membranous roof of the buccal space (with enclosed buccal fat) (Fig. 8) and around the medial border of the buccal space, where it turns in sharply to penetrate the buccinator to open into the oral cavity. The duct is stabilized by a fine but firm ligamentous band at the point of angulation that suspends it to the body of the zygoma, immediately medial to the origin of the masseter.

The exact level at which the duct crosses the masseter varies in proportion to the prominence of the accessory lobe of the parotid. The presence of a large accessory lobe has the effect of pushing the duct further inferiorly, to beneath the floor of the middle space rather than beneath its upper membranous boundary. In older individuals with more laxity related to attenuation of the masseter fascia, the duct tends to bulge into the floor of the space, but technically, by being beneath the floor membrane, the duct is outside the space.

The Buccal Space and Buccal Fat Pad

The buccal space is a deep soft-tissue space in the face. The membrane forming its roof is formed by the thin transparent prolongation of the masseteric fascia, which is deep fascia. The space is wedged-shaped—deeper at its posterior part against the masseter and tapered at its apex anteriorly where the fascial floor over the buccinator

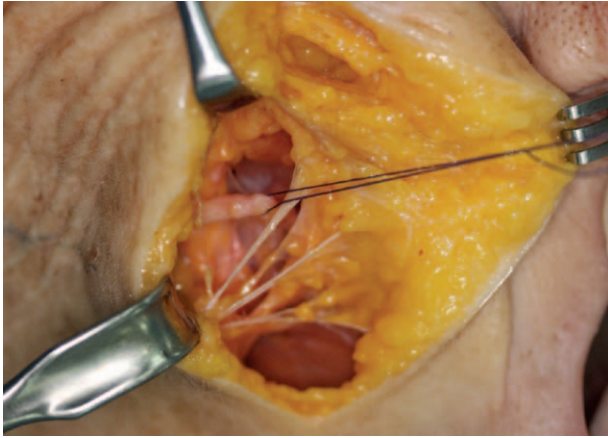


Fig. 8. Cadaver dissection through a cheek incision located at the anterior border of the masseter. Crossing medial to the masseter and the middle premasseter space into the anterior face are the parotid duct (in suture loop) and multiple buccal nerve branches.

joins with the underside of the roof formed by the SMAS of the medial cheek. The body of the buccal fat pad is within this part of the buccal space.

When the buccal fat is more prominent, its named prolongation, the masseter process of the buccal fat pad, emerges from the posterior aspect of the lower part of the body and extends through the anterior boundary into the middle premasseter space proper (Fig. 9).^{11,12} The process is variably developed; sometimes it is not in the space at all, and other times it fills the space. The presence of the masseter process is the reason why the buccal fat is readily accessed through the middle space. When the body of the buccal fat pad descends with aging, it bulges into the lower premasseter space through its upper anterior wall, but the fat does not freely enter into the lower space as it does in the middle space.⁹

The Soft Tissue Cephalad to the Middle Premasseter Space

A distance of 10 to 12 mm separates the prezygomatic space over the zygoma from the middle premasseter space. The surface of the masseter is entirely tendinous here as a result of its origin on the zygoma, although the surface is largely concealed by the accessory lobe of the parotid, covered by parotid fascia. Arising from the parotid fascia near the tip of the accessory lobe is a short stout ligament that fixes the overlying superficial fascia. This ligament is similar to and on the same vertical line as the zygomatic ligament above and the key masseteric ligaments below.

The zygomatic trunk of the facial nerve travels within soft fat deep in the interval between the lower edge of the zygoma and the accessory lobe

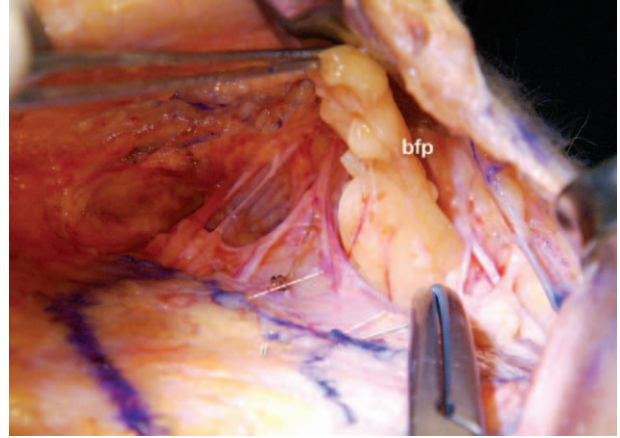
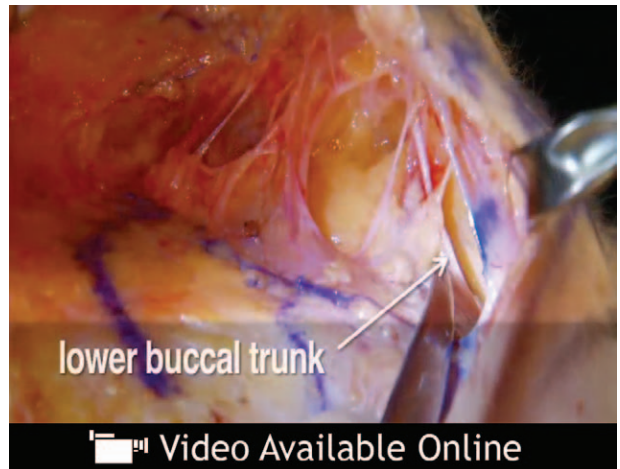


Fig. 9. The masseteric process of the buccal fat pad (*bfp*) passes through the anterior boundary and into the middle premasseter space.



Video 1. Supplemental Digital Content 1 demonstrates the anatomy of the middle premasseter space and its relations to the facial nerve branches as well as the parotid duct, <http://links.lww.com/PRS/A742>.

(Fig. 6). Between the lower edge of the accessory lobe and the upper border membrane of the middle premasseter space is a small, soft-tissue space, like a miniature version of the middle premasseter space.

The anatomy of the middle premasseter space and its relations to the facial nerve branches as well as the parotid duct are demonstrated in the **Video, Supplemental Digital Content 1**, which demonstrates the surgical dissection, <http://links.lww.com/PRS/A742>.

DISCUSSION

The recognition that there is more than one space over the masseter means the originally described “premasseter space”⁹ should be renamed

“the lower premasseter space.” Use of the lower pre-masseter space in face lift surgery provides safe sub-SMAS access to the anterior face. This provides for major redraping of aging laxity of the entire lower face, from the level of the oral commissure down.

The amount of tightening obtained is usually so significant and so readily obtained that it results in a disparity with the area immediately above the level of the oral commissure, because it is less effectively corrected. In order for the redraping to be harmonious, it becomes necessary to address the remaining ligament fixation that is responsible for the undercorrection of this area. Sub-SMAS access into the lower midcheek provides the exposure needed to release the ligamentous restraint provided by the firm masseteric cutaneous ligaments near the anterior border of the masseter.^{4,13} Only after this ligamentous resistance is sufficiently released can the SMAS redraping provide a similar degree of correction of the midcheek to blend with the amount of lower face correction.

Although surgical release in this area was described early on in sub-SMAS surgery,¹⁴ it has remained a limitation of sub-SMAS face lifts to obtain this required ligamentous release in the region of the upper masseter, where the anatomy is intrinsically more complex than over the lower masseter. The upper premasseter area is more involved in ligamentous fixation, whereas the lower premasseter area has more mobility associated with jaw movement.

For surgery here to become routine has required a clear description of the anatomy of the upper premasseter area at the least. The description of the middle premasseter space provided by this study is important, because it now provides a way to safely complete the composite correction of the lower face into the midcheek.

It is a somewhat unexpected finding that within the complex anatomy there is a “safe passage” right through the area of potential injury to the buccal trunks of the facial nerve to the sub-SMAS region of the lower midcheek. The safe passage is provided by the middle premasseter space, which is situated centrally between the upper and lower buccal trunks of the facial nerve. The nerves are a mirror image of each other, regarding anatomic relationships, as they remain behind their respective upper and lower boundary membranes of the space, and each rises up from the level of the floor to the underside of the SMAS roof, each on the inner side of its respective key masseteric ligament. The interconnecting nerve branch between the two trunks is medial to the space, which is forward of the key masseteric ligaments.

While the key ligaments at the anterior border of the masseter provide support for the SMAS overlying the mobile lower anterior face, the boundary membranes over the masseter do not seem to have a supportive function other than to protect the nerve trunks.

For the surgeon, this anatomy confirms the importance of the principle of “operating through the spaces.” The spaces appear and open readily with minimal blunt dissection. Failure of the space to open readily indicates that the dissection is not in the correct place. Forceful blunt dissection is not a substitute for being in the correct location. Operating through the spaces inherently protects the facial nerve branches, as they are located outside the spaces behind the membranous boundaries. When ligament release is required to obtain smooth redraping of the SMAS of the anterior face, it should only be performed when safe conditions are present. Safety with ligament release comes first from understanding the anatomy to appreciate the exact location and course of the nerve branches in relation to the ligaments. Second, the exposure obtained by preliminary blunt dissection of the spaces above and below the ligaments reduces the possibility of nerve injury during the process of ligament release. The sharp dissection required for this is localized and well controlled.

If access to the buccal space is required, the risk of damage to the interconnecting buccal nerve branch on the delicate membranous roof of the buccal space is minimized by opening through the masseter fascia immediately at the anterior border of the masseter. This provides entry from the middle premasseter space directly into the buccal space and proximal to the more anteriorly located nerve.

Although the middle premasseter space provides a safe surgical approach, its use is not devoid of risk, as it is amid important anatomy.¹⁵ The proximity of the nerves and parotid duct exposes them to potential risk during the initial dissection of the space, if it is not performed correctly, as well as during the processes of ligament release and suture fixation of the redraped SMAS.

CONCLUSIONS

1. The middle premasseter space is a safe space that provides reliable access to the anterior face.
2. The buccal trunks of the facial nerve traverse horizontally on either side of the space.
3. It is one of a vertical series of transversely oriented, true sub-SMAS soft-tissue spaces that overlie the anterior masseter.

Bryan Mendelson, F.R.C.S.E., F.R.A.C.S., F.A.C.S.
 The Center for Facial Plastic Surgery
 109 Mathoura Road
 Toorak, Victoria 3142, Australia
 drbryan@bmendelson.com.au

REFERENCES

- Mendelson BC. Facelift anatomy, SMAS, retaining ligaments and facial spaces. In: Aston SJ, Steinbrech DS, Walden JL, eds. *Aesthetic Plastic Surgery*. Philadelphia: Saunders Elsevier, 2009.
- Mendelson BC. Correction of the nasolabial fold: Extended SMAS dissection with periosteal fixation. *Plast Reconstr Surg*. 1992;89:822–833; discussion 834.
- Furnas DW. The retaining ligaments of the cheek. *Plast Reconstr Surg*. 1989;83:11–16.
- Stuzin JM, Baker TJ, Gordon HL. The relationship of the superficial and deep facial fascias: Relevance to rhytidectomy and aging. *Plast Reconstr Surg*. 1992;89:441–449; discussion 450.
- Mendelson B.C. Advances in understanding the surgical anatomy of the face. In: Eisenmann-Klein M, Neuhann-Lorenz C (eds). *Innovations in Plastic and Aesthetic Surgery*. Berlin: Springer; 2008;145–149.
- Moss CJ, Mendelson BC, Taylor GI. Surgical anatomy of the ligamentous attachments in the temple and periorbital regions. *Plast Reconstr Surg*. 2000;105:1475–1490; discussion 1491.
- Muzaffar AR, Mendelson BC, Adams WP Jr. Surgical anatomy of the ligamentous attachments of the lower lid and lateral canthus. *Plast Reconstr Surg*. 2002;110:873–884; discussion 897.
- Mendelson BC, Muzaffar AR, Adams WP Jr. Surgical anatomy of the midcheek and malar mounds. *Plast Reconstr Surg*. 2002;110:885–896; discussion 897.
- Mendelson BC, Freeman ME, Wu W, Huggins RJ. Surgical anatomy of the lower face: The premaseter space, the jowl, and the labiomandibular fold. *Aesthetic Plast Surg*. 2008;32:185–195.
- Furnas D. The superficial musculoaponeurotic plane and the retaining ligaments of the face. In: Psillakis JM (ed). *Deep Face-Lifting Techniques*. New York: Thieme Medical Publishers, 1994.
- Tart RP, Kotzur IM, Mancuso AA, Glantz MS, Mukherji SK. CT and MR imaging of the buccal space and buccal space masses. *Radiographics* 1995;15:531–550.
- Kahn JL, Wolfram-Gabel R, Bourjat P. Anatomy and imaging of the deep fat of the face. *Clin Anat*. 2000;13:373–382.
- Mendelson BC. Surgery of the superficial musculoaponeurotic system: Principles of release, vectors, and fixation. *Plast Reconstr Surg*. 2001;107:1545–1552; discussion 1553.
- Hamra ST. The deep plane rhytidectomy. *Plast Reconstr Surg*. 1990;86:53–61.
- Nagai K, Ichinose A, Kakizaki H, et al. Anatomical evaluation of facial nerve pathways and dissection of “premaseter space” for rhytidectomy in Asians. *Aesthetic Plast Surg*. 2012;36:534–539.

Contacting the Editorial Office

To reach the Editorial Office, please use the following contact information:

Plastic and Reconstructive Surgery®
 Rod J. Rohrich, M.D., Editor-in-Chief
 UT Southwestern Medical Center
 5959 Harry Hines Boulevard
 POB1, Suite 300
 Dallas, Texas 75390-8820
 Tel: 214-645-7790
 Fax: 214-645-7791
 E-Fax: 847-709-7534
 E-mail: PRS@plasticsurgery.org