

Intermittent Short Saphenous Vein Phlebotomy

An Effective Technique of Relieving Venous Congestion in the Distally Based Sural Artery Flap

Chin-Ho Wong, MBBS, MRCS, and Bien-Keem Tan, MBBS, FRCS

Introduction: Venous congestion is the main cause of failure in the distally based sural artery flap. Herein, we present our technique of phlebotomy to relieve flap congestion. Venous blood is intermittently drained via an exteriorized segment of the short saphenous vein until flap circulation normalizes.

Methods and Materials: From 2000 to 2005, 34 distally based sural artery flaps were performed. In all patients, an extra 5 cm of the short saphenous vein was incorporated with the flap during harvest. Fourteen flaps were noted to be congested after inset. In 2 patients, supercharging was performed. In the remaining 12 patients, intermittent phlebotomy was performed through an externalized segment of the short saphenous vein on the operating table and hourly thereafter until venous congestion improved.

Results: All flaps survived. The mean duration of phlebotomy was 30 hours, and mean blood loss in the first 24 hours was estimated to be 94 mL. The color of the flap was noted improved gradually over this period as it established a more efficient venous drainage.

Conclusion: Our approach of providing an additional venous outlet for congested flaps contributed to the favorable survival rate noted in this series. Intermittent phlebotomy was a simple and effective way to relieve venous congestion during the immediate postoperative period. As oscillating avalvular veins hypertrophied and multiplied during the ensuing 24–48 hours, venous circulation improved and the short saphenous vein spontaneously stopped draining. Phlebotomy improved flap survival and was a valuable temporizing measure to prevent critical congestion in flaps adapting to a new circulatory pattern.

Key Words: bleeding, congestion, distally based, phlebotomy, exsanguination, reverse, reliability, saphenous vein, safety, sural artery flap, lower limb, ankle, heel, neurocutaneous, venous anatomy, delay

(Ann Plast Surg 2007;58: 303–307)

Received May 25, 2006, and accepted for publication, after revision, July 1, 2006.

From the Department of Plastic, Reconstructive and Aesthetic Surgery, Singapore General Hospital, Singapore.

The authors did not receive any funding for this work and declare no conflict of interest in this present work.

Reprints: Bien-Keem Tan, MBBS, FRCS, Department of Plastic Reconstructive and Aesthetic Surgery, Singapore General Hospital, Outram Road, Singapore 169608. E-mail: bienkeem@singnet.com.sg.

Copyright © 2007 by Lippincott Williams & Wilkins

ISSN: 0148-7043/07/5803-0303

DOI: 10.1097/01.sap.0000238458.33475.ca

Soft-tissue defects of the lower-third leg, ankle, and heel are major reconstructive challenges. The distally based sural artery flap is increasingly gaining acceptance as an alternative to free flaps for injuries to this area.^{1–11} Since its first description by Masquelet et al¹ as a skin island flap supplied by the vascular axis of superficial sensory nerves, many authors have reported the use of this flap, with varying success rates.^{2–11} While favorable results have been reported, concerns about the reliability of this fasciocutaneous flap remain, particularly with large, extended flaps. Flap failure is often attributed to venous congestion.³ In this paper, we describe our approach of routinely harvesting an extra length of the short saphenous vein with our distally based sural artery flaps. This design has allowed us to perform intermittent phlebotomy for congested flaps through an externalized segment of the short saphenous vein.

PATIENTS AND METHODS

Operative Technique

The patient is placed in a prone position. Preoperative marking of the lesser saphenous vein and peroneal perforator in the lateral aspect of the distal leg with a handheld Doppler (8 MHz) is done in all patients. The axis of the distally based sural artery flap corresponds to the course of the sural nerve. This is the line joining the midpoint of the popliteal fossa and the point midway between the posterior border of the lateral malleolus and the Achilles tendon. A racket or teardrop-shaped flap is designed with its pivot point corresponding to the peroneal perforators supplying the flap. The flap is designed slightly larger than the defect to make allowance for flap swelling. Under tourniquet control, the flap is elevated at the subfascial plane. We commence the elevation of the flap proximally, identifying the sural nerve, short saphenous vein, and the median sural artery, which are included with the flap. An additional 5 cm of the short saphenous vein is mobilized as a venous pedicle, which is exteriorized and temporarily occluded with a microvascular clamp (TKMV-1; Synovis, Birmingham, AL) and divided. Dissection is then carried distally to the location of the peroneal perforators, which are 4 to 5 cm above the lateral malleolus. The width of the pedicle at its base is about 1.5 cm to minimize bulkiness at the pivot point. The flap is transposed without tunneling to avoid compression. Any intervening skin bridge between the

pivot point and the defect is incised and opened to inset the racket handle portion of the flap. The donor site is closed primarily or skin grafted. Assessment of venous congestion is done about 30 minutes after flap inset. Venous congestion is determined clinically by the flap's color and rapidity of capillary refill. If congestion is present, the short saphenous vein is released for blood to drain. If congestion is not observed after 30 minutes, the short saphenous vein is occluded with a microvascular clamp, which could be released as and when needed. This is done in case the flap develops congestion in the ward as the flap warms up. The skin around the vein is left unstitched to prevent compression of the vein. The clamp is released hourly for a few minutes and flushed with heparin saline to facilitate bleeding. If the vein fails to flow with repeated usage, it is probed with a sterile micro-forceps, and any visible clot is extracted. If it becomes shriveled and dry, the vein can be cut back to a fresh portion, which expands better. Occasionally, if the vein fails to flow despite such measures, we infuse the vein with heparinized saline. This needs to be done under slight pressure to overcome resistance from the valves. To keep the field around the vein clean, handling of the microclamp is done with sterile gloves and forceps. When not in use, the vein is covered with a piece of saline-soaked gauze. This is done until congestion improves and the vein spontaneously stops flowing. Patients are kept on prophylactic antibiotics postoperatively until the wound is closed by secondary suture.

PATIENTS AND METHODS

From 2000 to 2005, 34 distally based sural artery flaps were performed. In all patients, a length of the short saphenous vein was harvested as a venous pedicle. Fourteen flaps developed venous congestion after flap elevation and inset. In 2 patients, venous supercharging to dorsal veins of the foot was performed. In the remaining 12 patients, intermittent phlebectomy using the externalized portion of the short saphenous vein was performed. The patients' profile, comorbidities, and postoperative outcome are detailed in Table 1.

RESULTS

Surgery was performed for a spectrum of clinical conditions, including trauma, exposed implants, osteomyelitis, diabetic wounds, septic arthritis, necrotizing fasciitis, and ankle contractures. All flaps survived in our 34 patients. Flap congestion was noted in 14 flaps (41%) intraoperatively. In 2 of these flaps, venous supercharging was employed. In the remaining 12 flaps, no suitable recipient veins were found in the vicinity, and the phlebectomy technique was employed. The veins remained patent for a mean of 30 hours (range, 9 to 56). Venous congestion improved in all 12 flaps that were intermittently bled, and these remained healthy after the lesser saphenous vein stopped flowing. The amount of blood lost from each clamp release was estimated to range from 2 to 5 mL (estimated by weight). The total volume of blood loss in the first 24 hours was estimated to be 94 mL (range, 55 to

TABLE 1. Patients' Summary

Patient	Age	Sex	Comorbidities	Wound Characteristics	Site of Defects	Techniques	Size of Flap (cm)	Complications
1	34	M	Nil	Wound breakdown post-ORIF of the ankle	Lower third of leg	Inclusion of gastrocnemius muscle, IP	8 × 12	Nil
2	69	M	Peripheral vascular disease	Septic arthritis	Ankle	IP	10 × 5	Delayed healing
3	54	F	Diabetes and peripheral vascular disease	Ulcer with osteomyelitis	Heel	IP	20 × 5	Nil
4	32	M	Nil	Degloving injury	Heel to midfoot	IP	30 × 10	Nil
5	59	F	Diabetes with peripheral vascular disease	Chronic ischemic ulcer	Ankle	Delay, IP	9 × 14	Delayed healing
6	55	M	Nil	Tendo-Achilles repair wound breakdown	Ankle	IP	4 × 15	Nil
7	45	M	Diabetes	Necrotizing fasciitis	Ankle	IP	7 × 16	Nil
8	58	M	Peripheral vascular disease	Lateral malleolar ischemic ulcer	Lateral malleolus defect	Delay, IP	12 × 5	Nil
9	30	M	Nil	Degloving injury with fractured calcaneum	Heel and midfoot	IP	22 × 8	Tip necrosis, healed with dressings
10	23	M	Nil	Degloving injury	Distal third of leg	IP	14 × 6	Nil
11	48	M	Nil	Degloving injury	Foot dorsum	IP	18 × 8	Nil
12	35	M	Nil	Degloving injury	Ankle	IP	12 × 5	Nil

IP, intermittent phlebectomy.

156). None of our patients required blood transfusion as a result of bloodletting. Patients were followed up for a mean of 19 months (range, 8 to 49 months). All 12 flaps survived. Complications in these 12 patients included 1 superficial tip necrosis that healed with dressings and 1 wound infection. At follow-up, none of our patients complained of any discomfort resulting from the sacrifice of the sural nerve. All flaps provided stable, durable skin for defect coverage, with acceptable cosmesis.

CASE REPORTS

Case 1

A 34-year-old man sustained an ankle fracture after a road traffic accident. Open reduction and internal fixation were complicated by wound dehiscence, resulting in exposure of implants. The metal implants were removed, and an 8-by-12-cm distally based sural artery flap was raised (Fig. 1A). A cuff of gastrocnemius muscle was included with the flap to fill the significant dead space left after debridement at

the defect site (Fig. 1B). The donor site was closed with split skin graft. The flap was noted to be congested after inset, and phlebotomy via the exteriorized short saphenous vein was commenced (Fig. 1C). Hourly phlebotomy was performed in the ward until the vein eventually stopped flowing (after 28 hours) (Fig. 1D–F). The flap survived completely, and he was well at 10-month follow-up.

DISCUSSION

Venous congestion is an area of considerable concern in distally based sural artery fasciocutaneous flap and is one of the main reasons for failure, particularly when a large flap is needed.³ While the exact incidence has not been previously reported, it was seen in 41% of our patients. The overall flap survival rate in our series of 34 patients was 100%. This favorable outcome can in part be attributed to our approach of selectively performing phlebotomy (bloodletting) or supercharging for flaps that became congested after flap inset.¹² Venous congestion causes backpressure buildup that progres-

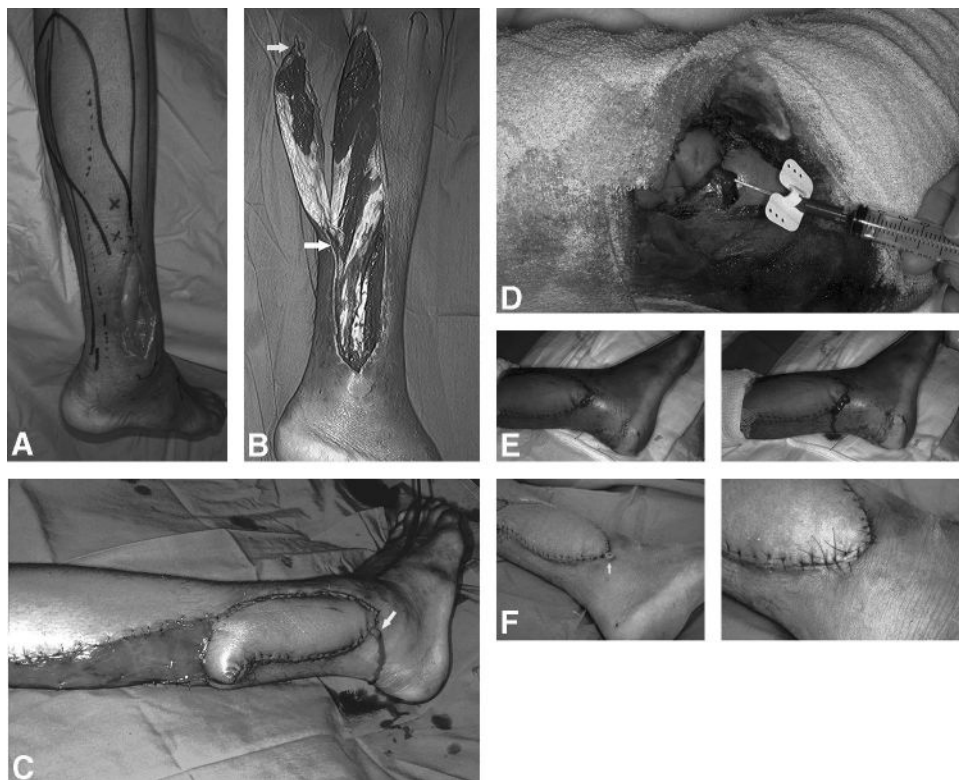


FIGURE 1. A, Lower-third defect resulting from an extruded implant. Coverage with a distally based sural artery flap was planned. "X" marked the location of the distal leg perforators as determined by preoperative handheld Doppler assessment. B, The short saphenous vein was harvested long and a microvascular clamp was applied (top arrow). A cuff of gastrocnemius muscle was included with the flap to increase reliability of the distal tip and to fill dead space at the defect. The flap was dissected distally until the distal leg perforators were encountered (bottom arrow). C, After flap inset, congestion was noted. The short saphenous vein was externalized and bled to relieve venous congestion (arrow). D, The microclamp was released hourly and irrigated with heparin saline to flush out any clots. E, The flap was slightly congested prior to release of microvascular clamp (right). The flap color improved after bleeding (left). This is a low-flow flap, and blood loss every time the clamp was released was not excessive (estimated to range from 2 to 5 mL). None of our patients required blood transfusion as a result of the use of this technique. F, After the vein stopped draining, it is excised (arrow) (right). The wound is closed by secondary suture under local anesthesia (left).

sively impairs flow in the capillary bed, arterioles, and eventually arterial inflow.¹³ Tissue ischemia sets up a vicious cycle that eventually results in tissue necrosis. This vicious cycle can be broken by providing an alternative escape route for venous blood, thereby preventing congestion from reaching a critical level.

Various techniques have been described to relieve venous congestion, and these can broadly be classified into *microsurgical* and *nonmicrosurgical techniques*.^{14–21} Both these techniques have been shown to improve flap survival. The former entails providing an additional channel for venous outflow from the flap by means of supercharging. In the context of the distally based sural artery flap, this involves venous microanastomosis of the short saphenous vein to the dorsal veins of the foot.²¹ However, recipient veins are usually not available in the vicinity of the defect because of infection or trauma. Nonmicrosurgical techniques entail bleeding the flap intermittently. These include the use of medicinal leeches, dermal bleeding, and phlebotomy.^{14–20,28–30} Medicinal leeches (*Hirudo medicinalis*) are the most established technique of alleviating venous congestion. While leeches are undoubtedly effective, their use can be problematic and distressing to patients.^{22,28} Smoot et al¹⁸ have demonstrated in their experimental study of congested epigastric flap in rats that mechanical exsanguination is superior to the use of leeches in restoring capillary perfusion to the flap. Subsequently, La Scala et al¹⁴ and Hartrampf et al¹⁵ devised techniques of bleeding flaps by introducing cannulae into the outflow vein to improve venous congestion in the reverse radial forearm and TRAM (transverse rectus abdominis myocutaneous) flaps, respectively. These authors have coined the term *mechanical leeching* and found it effective in enhancing flap survival when used for 24 to 48 hours.^{14,15,29} Our technique is basically the same, except that venous cannulation is omitted because of the extra length of vein available for direct drainage. This avoids problems such as cannula clogging and dislodgement.

The distally based sural artery flap has 2 venous drainage systems, namely, the short saphenous vein and the vena comitantes accompanying the sural nerve (Fig. 2). These 2 systems are connected by oscillating avalvular veins.²⁷ Blood draining the flap via the short saphenous vein has to flow in a retrograde direction, whereas that in the vena comitantes accompanying vasa nervorum of the sural nerve flows antegradely towards the distal leg perforators.^{23–25} The short saphenous vein collects venous blood from its tributaries serving the entire flap but has no outflow; hence, blood has to be rechanneled into the deep venous system via oscillating avalvular veins to the vena comitantes accompanying the sural nerve that eventually drain into the peroneal perforator veins. This delicate network channels blood from the superficial to the deep venous systems. According to Taylor et al,²⁷ these oscillating avalvular veins multiply and hypertrophy in response to increased flow, as is the situation after flap elevation. Hence, intermittent phlebotomy is a form of delay which allows new venous channels to develop.²⁶

The duration of intermittent phlebotomy or exsanguination reported in the literature varies from <24 hours to 9 days.^{19,22} In an extensive review on the use of leech therapy, de Chalain²² reported a mean duration of 4.2 days. These data

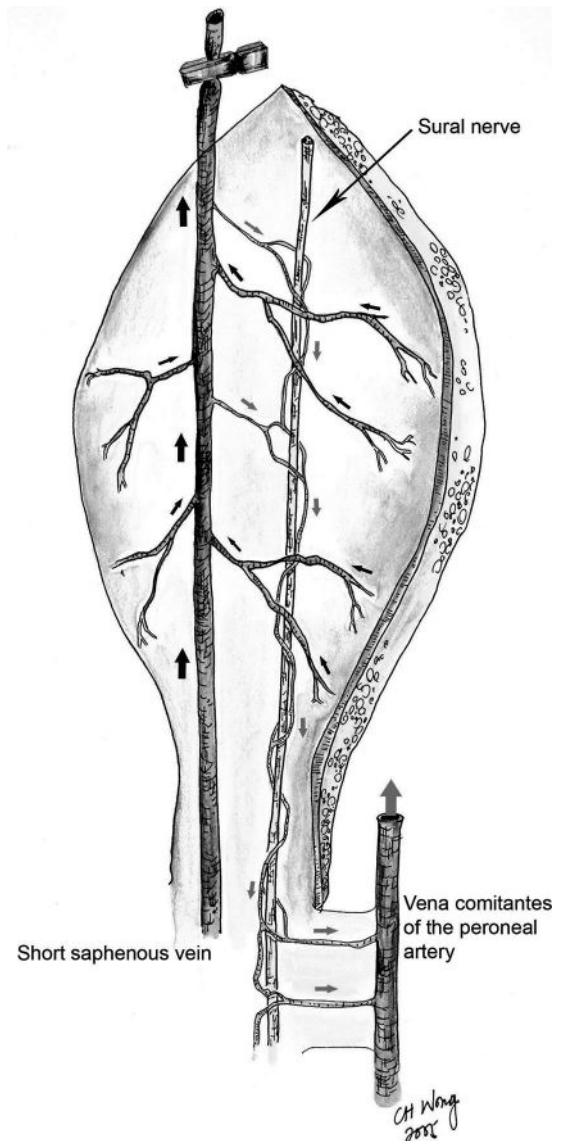


FIGURE 2. Venous drainage of the distally based sural artery flap. The short saphenous vein drains most areas of this flap and is the main “collecting vein.” Its reverse flow orientation however prevents sufficient venous outflow. It communicates with the vena comitantes accompanying the sural nerve via oscillating avalvular veins, which eventually drain blood via the distal leg perforator veins into the peroneal system. These oscillating avalvular veins become more efficient as they hypertrophy and multiply in response to the increased demand. As a temporizing measure to transiently relieve venous congestion and prevent critical congestion, phlebotomy can be performed through the externalized portion of the short saphenous vein.

were, however, derived from cases where bleeding was used as the sole means of venous outflow while awaiting sufficient neovascularization to provide an alternative drainage. When used in the distally base sural artery flap, a duration of 24–48 hours was enough as there was already a functional deep venous system draining the flap.

The mean total volume of blood loss in the first 24 hours was estimated to be 94 mL (range, 55 to 156). This is much less than in cases in which bleeding was used as a sole means of venous drainage.³⁰ None of our patients developed anemia with the hourly phlebotomy regimen as bleeding was self-regulating. We observed that as the deep system becomes more efficient over time, outflow from the short saphenous vein decreased and eventually ceased. Phlebotomy served to intermittently decompress the system, which prevent stasis and clotting. Furthermore, the distally based sural artery flap is a low-flow flap receiving arterial inflow from the peroneal septocutaneous perforators in the distal leg. These perforators channel far less blood into the flap compared with flaps based on axial arteries such as the radial forearm or anterior tibial artery flaps. The effectiveness of this technique in improving flap survival, coupled with the relatively low amounts of blood loss through the phlebotomy, makes this a viable alternative for relieving venous congestion in distally based sural artery flaps.

REFERENCES

- Masquelet AC, Romana MC, Wolf G. Skin island flap supplied by the vascular axis of the sensitive superficial nerves: anatomical study and clinical experience in the legs. *Plast Reconstr Surg*. 1992;89:1115–1120.
- Price MF, Capizzi PJ, Watterson PA, et al. Reverse sural artery flap: caveats for success. *Ann Plast Surg*. 2002;48:496–504.
- Almeida MF, da Costa PR, Okawa RY. Reverse-flow island sural flap. *Plast Reconstr Surg*. 2002;109:583–591.
- Singh S, Naasan A. Use of distally based superficial sural island artery flaps in acute open fractures of the lower leg. *Ann Plast Surg*. 2001;47:505–510.
- Huisinga RL, Houpt P, Dijkstra R, et al. The distally based sural artery flap. *Ann Plast Surg*. 1998;41:58–65.
- Dolph JL. The superficial sural artery flap in distal lower third extremity reconstruction. *Ann Plast Surg*. 1998;40:520–522.
- Hasegawa M, Torii S, Katoh H, et al. The distally based superficial sural artery flap. *Plast Reconstr Surg*. 1994;93:1012.
- Tosun Z, Ozkan A, Karacor Z, et al. Delaying the reverse sural flap provides predictable results for complicated wounds in diabetic foot. *Ann Plast Surg*. 2005;55:169–173.
- Yilmaz M, Karatas O, Barutcu A. The distally based superficial sural artery island flap: clinical experiences and modifications. *Plast Reconstr Surg*. 1998;102:2358.
- Al-Qattan MM. Lower-limb reconstruction utilizing the reverse sural artery flap-gastrocnemius muscle cuff technique. *Ann Plast Surg*. 2005;55:174–178.
- Al-Qattan MM. A modified technique for harvesting the reverse sural artery flap from the upper part of the leg: inclusion of a gastrocnemius muscle “cuff” around the sural pedicle. *Ann Plast Surg*. 2001;47:269–274.
- Baumeister SP, Spierer R, Erdmann D, et al. A realistic complication analysis of 70 sural artery flaps in a multimorbid patient group. *Plast Reconstr Surg*. 2003;112:129–140.
- Kerrigan CL, Wizman P, Hjortdal VE, et al. Global flap ischemia: a comparison of arterial versus venous etiology. *Plast Reconstr Surg*. 1994;93:1485–1497.
- La Scala GC, Carroll SM, Forrest CR, et al. Use of a mechanical leech in a reverse-flow radial forearm flap: case report. *J Reconstr Microsurg*. 2001;17:335–340.
- Hartrampf CR Jr, Drazan L, Noel RT. A mechanical leech for transverse rectus abdominis musculocutaneous flaps. *Ann Plast Surg*. 1993;31:103–105.
- Rao P, Bailie FB, Bailey BN. Leechmania in microsurgery. *Practitioner*. 1985;229:901.
- Conforti ML, Connor NP, Heisey DM, et al. Evaluation of performance characteristics of the medicinal leech (*Hirudo medicinalis*) for the treatment of venous congestion. *Plast Reconstr Surg*. 2002;109:228–235.
- Smoot EC, Ruiz-Inchaustegui JA, Roth AC. Mechanical leech therapy to relieve venous congestion. *J Reconstr Microsurg*. 1995;11:51–55.
- Cottler PS, Gampper TJ, Rodeheaver GT, et al. Evaluation of the clinically applicable exsanguination treatments to alleviate venous congestion in animal skin flap model. *Wound Repair Regen*. 1999;7:187.
- Foucher G, Henderson HR, Maneau M, et al. Distal digital replantation: one of the best indications for microsurgery. *Int J Microsurg*. 1981;3:263.
- Tan O, Atik B, Bekerecioglu M. Supercharged reverse-flow sural flap: a new modification increasing the reliability of the flap. *Microsurgery*. 2005;25:36–43.
- de Chalain TM. Exploring the use of the medicinal leech: a clinical risk-benefit analysis. *J Reconstr Microsurg*. 1996;12:165–172.
- Nakajima H, Imanishi N, Fukuzumi S, et al. Accompanying arteries of the lesser saphenous vein and sural nerve: anatomic study and its clinical applications. *Plast Reconstr Surg*. 1999;103:104–120.
- Nakajima H, Imanishi N, Fukuzumi S, et al. Accompanying arteries of the cutaneous veins and cutaneous nerves in the extremities: anatomical study and a concept of the venoadipofascial and/or neuroadipofascial pedicled fasciocutaneous flap. *Plast Reconstr Surg*. 1998;102:779–791.
- Imanishi N, Nakajima H, Fukuzumi S, et al. Venous drainage of the distally based lesser saphenous sural veno-neuroadipofascial pedicled fasciocutaneous flap. *Plast Reconstr Surg*. 1999;103:494–498.
- Dhar SC, Taylor GI. The delay phenomenon: the story unfolds. *Plast Reconstr Surg*. 1999;104:2079.
- Taylor GI, Caddy CM, Watterson PA, et al. The venous territories (venosomes) of the human body: experimental study and clinical implications. *Plast Reconstr Surg*. 1990;86:185.
- Gideroglu K, Yildirim S, Akan M, et al. Immediate use of medicinal leeches to salvage venous congested reverse pedicled neurocutaneous flaps. *Scand J Plast Reconstr Surg Hand Surg*. 2003;37:277–282.
- Eker G, Akan IM, Aydogdu E, et al. Salvage of neurocutaneous flaps with venous congestion using intravenous cannula. *Plast Reconstr Surg*. 2003;112:1191–1192.
- Al-Qattan MM. A new technique to salvage digital replantation with compromised venous outflow. *J Hand Surg [Br]*. 2001;26:582–583.