



ELSEVIER



Use of the slit arteriotomy for end-to-side arterial anastomosis in free-tissue transfers to the extremities[☆]

Bien-Keem Tan^{a,*}, Chin-Ho Wong^a, Winston Chew^b, Soo-Wan Hong^a

^a Department of Plastic, Reconstructive and Aesthetic Surgery, Singapore General Hospital, Singapore

^b Department of Orthopaedics, Tan Tock Seng Hospital, Singapore

Received 27 December 2007; accepted 4 May 2008

KEYWORDS

Technique;
Advantages;
Outcome;
Microsurgery;
Simulation model;
Clinical experience

Summary *Introduction:* The purpose of this study was to demonstrate the reliability and advantages of the slit arteriotomy for end-to-side arterial anastomosis.

Materials and methods: Sixty free flaps for reconstruction of the upper and lower extremities were re-vascularised using this technique. Flaps used were: gracilis (20), latissimus dorsi (18), rectus abdominis (6), lateral arm (6), fibula (3), radial forearm (4), scapular (1) and anterolateral thigh (2).

Technique: A double microclamp is applied. Using a 30° microknife, a longitudinal slit is made on the recipient vessel. The clamps are then approximated slightly. This slackens the segment bearing the slit and opens up the slit to facilitate placement of sutures. Beginning at the heel, interrupted sutures are placed in such a way as to feed the redundancy of the donor artery wall towards the toe of the anastomosis. A slightly oversized slit is used to stretch the donor vessel, which due to its inherent elastic recoil keeps the anastomosis patent. Once the tourniquet is released, blood flow resumes and the slit forms an elliptical opening. A video is available for viewing at our website: www.microflap.com.

Results: The arterial patency rate was 98%. The mechanical advantage of the slit arteriotomy construct was demonstrated through computer simulation on a finite-element analysis model.

Conclusion: The slit arteriotomy is simple, reliable, and can be consistently used in the transfer of free flaps to the extremities. As no portion of the recipient vessel wall is excised, the anastomotic diameter is increased. This promotes blood flow through the anastomosis.

© 2008 Published by Elsevier Ltd on behalf of British Association of Plastic, Reconstructive and Aesthetic Surgeons.

[☆] Presented in parts at the American Society for Reconstructive Microsurgery Meeting, Hawaii, USA, January 2003, and the International Plastic Reconstructive Aesthetic Society Meeting, Sydney, Australia, August 2003 and 11th Kleinert Society Clinical Reunion, October 2003, Louisville, Kentucky.

* Corresponding author. Address: Department of Plastic, Reconstructive and Aesthetic Surgery, Singapore General Hospital, Outram Road, Singapore 169608. Tel.: +65 6321 4686; fax: +65 6220 9340.

E-mail address: bienkeem@singnet.com.sg (B.-K. Tan).

The use of the end-to-side arterial anastomosis in extremity reconstruction was described and popularised by Godina in the 1970s.¹ The advantages of this technique include: decreased vessel spasm; elimination of vessel mismatch and preservation of the distal run-off.^{1–5} In his original description, the arteriotomy was created with a pair of microscissors by excising a portion of the vessel wall. This gives an elliptical hole which efficiently shunts blood into the flap. This technique is widely practiced today,^{6–9} with modifications such as using a vessel punch for creating the arteriotomy.^{10,11}

The routine use of the slit-type arteriotomy in conventional vascular surgery with consistent success led us to wonder if a similar technique could be employed in microvascular surgery. Issues that are currently unclear include: Is it necessary to excise a portion of the recipient vessel's wall? Can the slit be used safely in small vessels where perfusion pressures are less? If the opening is not enlarged by wall excision, is there a risk of it closing? Are there advantages of the slit over the hole arteriotomy? The purpose of this paper is to describe our observations using the slit end-to-side anastomosis technique, and to highlight its reliability and potential for extremity free flap reconstruction.

Patients and methods

Between 1997 and 2004, 60 free flaps for extremity reconstruction were performed in 55 patients. Flaps used are summarised in Table 1. The most common indication was trauma. The recipient vessels used in the lower limb were the posterior tibial (58%), anterior tibial (22%) and superficial femoral (5%) arteries. In the upper extremity, we used the radial (12%) and the brachial (3%) arteries. In three patients, chain-linked double free flaps were used to cover extensive wounds.¹⁴

End-to-side anastomosis technique

The procedure is performed under tourniquet. A 3 cm segment of recipient artery is prepared by clearing away perivascular tissue and ligating side branches. The position of the slit on the recipient is determined by the intended

configuration of the end-to-side anastomosis, which in turn is dictated by anatomic considerations. It could be an anterior take-off which is preferred when the recipient artery is deep, e.g. the proximal portion of the anterior tibial artery; or a lateral take-off when it is superficial, e.g. the dorsalis pedis artery. A lateral take-off reduces the risk of compression. The orientation of the planned arteriotomy should be marked with a surgical pen, and the arterial segment is rotated between double microclamps to an optimal position for ease of performing the anastomosis (Figure 1A).

The donor artery is bevelled 30–45° by trimming its ends with a pair of microscissors. This gives a take-off angle of between 60 and 45°. Alternatively, one corner of the vessel is slit open and the corners trimmed to create a hood. The recipient segment is then mounted on a double microclamp. A longitudinal slit is made using a 15 or 30° microknife, cutting in opposing directions to ensure that the corners are even. The clamps are then approximated slightly to open the slit (Figure 1B). The lumen is irrigated to clear away blood and inspected to see if the posterior wall had been pierced – if so, repair is undertaken immediately.

Beginning at the heel, interrupted sutures are placed sequentially, feeding the donor's redundancy towards the toe (Figure 1C). We commonly used 9/0 Ethilon (BV 130-5, Ethicon, Inc.) sutures for the anastomosis. If the slit is deficient, it could be extended with the microknife midway through the operation in a 'cut-as-you-go' manner. In this way the donor vessel stretches out nicely over the slit. If the slit is too long, the excess is simply repaired with interrupted stitches. A common practice is to fix the toe and the heel as an initial step, but this tethers the donor down, reduces exposure and prematurely fixes the length of the slit.

When suturing, the needle bite on the thinner donor vessel is taken first, followed by the thicker recipient, as this keeps the edges well everted and buttressed. As much as possible, the needle is passed from inside-to-outside on the recipient artery, to tag the intima. Variations of needle grasping techniques are illustrated in Figure 1D–H. When approaching the corners, the sutures are placed more obliquely to skew the pull on the slit.

Over on the far side, suturing adjacent to the corners is the most difficult and these should be placed first. The suturing sequence aims to finish at the midlateral point (Figure 1E–I). For better visualisation, the final three sutures are left untied until all are in position. The end product should be a well stretched donor vessel end cupped over the slit arteriotomy. A video of our suture technique is available for viewing at our website at www.microflap.com.¹⁷

Postoperatively the patients are kept well hydrated and blood transfusion is given to keep the haemoglobin level around 10 g%. Anti-thrombotic agents are not routinely given.

Results

Overall success rate was 95% (one arterial failure and two venous failures out of 60 flaps). The sole arterial failure was due to compression at the take-off at the dorsalis pedis artery. We have since used a lateral take-off when the vessel is superficial. One venous failure resulted from an unsuspected deep vein thrombosis and the other was due to venous mismatch. In both cases the arteries were patent at

Table 1 Upper and lower extremity reconstruction

| Types of flaps | No. of flaps performed |
|--------------------------|------------------------|
| Lateral arm flap | 6 |
| Gracilis flap | 20 |
| Anterolateral thigh flap | 2 |
| Latissimus dorsi flap | 17 |
| Rectus abdominis flap | 7 |
| Fibula/peroneal flap | 3 |
| Radial forearm flap | 4 |
| Scapular flap | 1 |
| Total | 60 |

Arterial success rate 98%

(1 failure due to compression at the take-off)

Overall success rate 95%

(1 arterial failure, 2 venous failures)

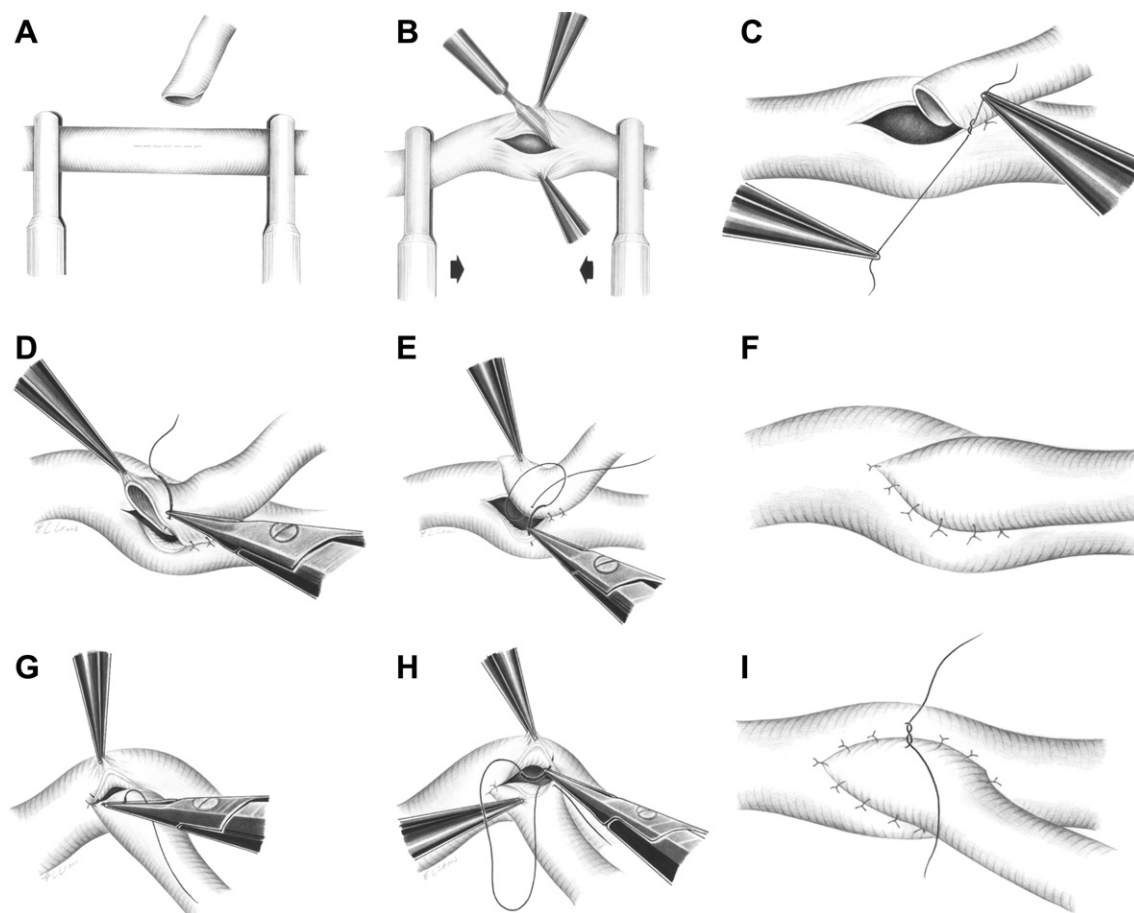


Figure 1 (A) A 3 cm segment of a recipient artery is prepared. (B) A longitudinal slit is made using a 30° microknife, the clamps are then approximated to open the slit. (C–F) Beginning at the heel, interrupted sutures are placed sequentially, feeding the redundant vessel towards the toe. (G–I) On the far side, the suturing of the corners is done first terminating in the middle portion where the exposure is good. The final three sutures are left untied until all are in position. The end product should be a well stretched-out donor vessel end cupped over the slit arteriotomy.

the time of re-exploration. The non-viable flaps were simply detached by clamping off the donor artery without interrupting flow in the recipient artery. None of the other flaps required re-exploration.

'No-flow' was encountered in four patients immediately after revascularisation. In two patients the recipient arteries were in spasm because of the cold. Flow resumed after re-warming and topical papavarine application. If the donor artery is in spasm, the distal run-off could be intermittently occluded with a single microclamp to preferentially shunt blood into the flap. The reason for poor flow in the third and fourth patients was white thrombus formation. In one, the thrombus spontaneously washed away after a dose of intravenous heparin, while in the other, evacuation through re-opening the anastomosis was required. Postoperative intravenous heparin was administered in these cases.

Discussion

The advantages of end-to-side anastomosis for extremity reconstruction are well established.^{1–5} However, it is unclear whether the slit arteriotomy is reliable and if it

could be routinely used in preference to 'hole arteriotomy'.^{12,13} Proponents of the hole technique prefer to excise a portion of the vessel wall for better visualisation during suturing and they submit that the patency is better.^{6–8} This series attests to the dependability of the slit technique with an arterial anastomotic patency rate of 98%. A slit which can have its length adjusted to the diameter of the donor vessel is easily created with the microknife. There is no narrowing of the recipient vessel because of the patch arterioplasty effect. If the anastomosis has to be re-sited up- or downstream, the slit is simply repaired without constricting the recipient artery. The main disadvantage is that exposure is less compared to that of a hole, thus requiring the help of a trained assistant. If assistance is unavailable, micro hook retractors may be employed. We prefer the interrupted suturing technique for better distribution of tension and this facilitates eccentric suture placement – all of which contribute to deforming the slit opening. From a biomechanical standpoint, maximal stresses should be imposed on the heel and toe areas to keep the slit open, similar to the clasp action on a spring-top coin purse.

An analysis of factors that contribute to slit opening using computer modelling confirmed the reliability of the slit arteriotomy under physiological conditions (LS-DYNA3D software, Livermore Software Technology Corp, Livermore, CA, USA)¹⁵ (Figure 2). Three factors contribute to maintaining slit patency, namely, residual stress, the coupling effect of the donor and recipient vessels and blood pressure. Biological tissues in the physiological state are under 'stress'. An artery which is cut transversely will retract from the cut end due to contraction of the longitudinal fibres. Similarly, when a longitudinal slit is made the circular fibres contract to open the slit. This effect contributed approximately 20% to slit opening in our model. The second factor is a coupling effect when two vessels are joined. The slit is deformed by the donor vessel, which generates a patch arterioplasty effect. Additionally, elastic recoil of the donor in the longitudinal axis of the recipient prisms the slit open. This factor contributes about 40% to slit opening. The thicker the donor, the wider would be the slit. Holding other factors constant, we observed that for a donor whose wall measures 0.3 mm thick, the slit width is 1.21 mm; and for a 0.4 mm thick donor, the result is a 1.31 mm slit. The third factor is blood pressure which contributes another 40% to opening. Blood pressure is the force that propels the blood through the segment bearing the anastomosis and its effect is evident with tourniquet release. Spasm or stenosis greatly increases resistance to flow, since diameter is

inversely proportional to resistance, based on Poiseuille's law ($R \propto 1/D^4$). It follows then that, contrary to popular thinking, the slit arteriotomy is in fact advantageous for flow because there is a dilatation at the anastomotic site (Figure 2).

The use of a T-anastomosis has been described recently.^{7,16} To perform this anastomosis, the donor vessel needs to have a configuration in which there are proximal and distal stems for anastomosis. Practically all conventional flaps with large axial vessels lend themselves well to this technique. Among these, the subscapular and the lateral circumflex femoral arterial systems are the most popular. In essence, the T-anastomosis is an end-to-end anastomosis with reconstitution of the distal run-off. The purported advantage of this technique is that the T-joint is a natural one, making it less susceptible to kinking and thrombosis. However, the anastomotic sites would have to be well chosen to ensure good vessel match.

In our practice, the slit end-to-side technique is indispensable to extremity reconstruction and it is especially useful in the single-vessel leg and in situations where the recipient veins are small or poorly expansile. We have observed that since arterial inflow is regulated according to the physiological demands of the flap, not all the blood shunts into the flap, unlike in an end-to-end configuration. Consequently, the flap is less congested, and venous drainage is within the coping limits of the recipient veins. Perforator and small free flaps would benefit from such an improved haemodynamic state.

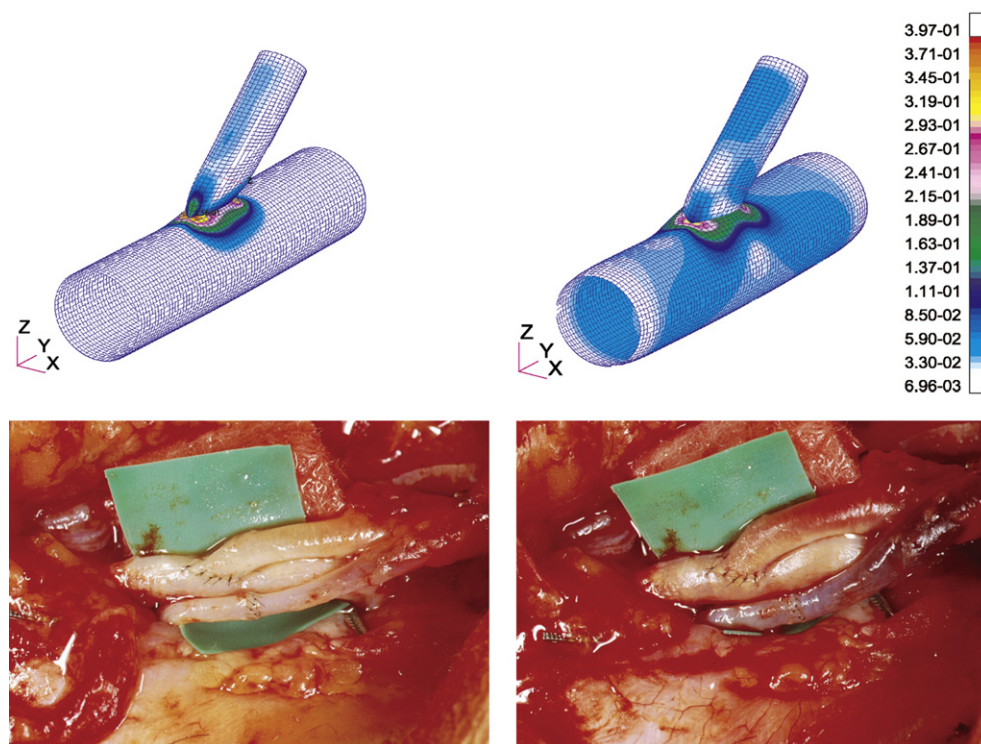


Figure 2 Computer simulation of an ideal end-to-side anastomosis before (above left) and after (above right) resumption of blood flow. The cooler colours denote areas of low stresses and the warm colours denote areas of high stresses. The areas of maximal stress are concentrated at the heel and toe where there is maximal deformation. Corresponding clinical pictures of an end-to-side anastomosis before (below left) and after (below right) release of the tourniquet.

Acknowledgements

We thank Mr Michael Leow for the artwork.

The authors declare no conflict of interest in this present work. This work was funded by a research grant from the Department of Clinical Research, Singapore General Hospital, Singapore.

References

- Godina M. Preferential use of end-to-side arterial anastomoses in free flap transfers. *Plast Reconstr Surg* 1979 Nov;**64**:673–82.
- Samaha FJ, Oliva A, Buncke GM, et al. A clinical study of end-to-end versus end-to-side techniques for microvascular anastomosis. *Plast Reconstr Surg* 1997 Apr;**99**:1109–11.
- Dotson RJ, Bishop AT, Wood MB, et al. End-to-end versus end-to-side arterial anastomosis patency in microvascular surgery. *Microsurgery* 1998;**18**:125–8.
- Nam DA, Roberts III TL, Acland RD. An experimental study of end-to-side microvascular anastomosis. *Surg Gynecol Obstet* 1978;**147**:339.
- Zoubos AB, Seaber AV, Urbaniak JR. Hemodynamic and histological differences in end-to-side anastomoses. *Microsurgery* 1992;**13**:200.
- Sen C, Agir H, Iscen D. Simple and reliable procedure for end-to-side microvascular anastomosis: the diamond technique. *Microsurgery* 2006;**26**:160–4.
- Verhelle NA, Heymans O. How to deal with difficult microsurgical end-to-side anastomoses. *Microsurgery* 2005;**25**:203–8.
- Hall EJ. End-to-side anastomoses: a model and a technique with clinical application. *J Microsurg* 1980 Dec;**2**:106–12.
- Dash H, Kononov A, Maloney III J, et al. A simple arteriotomy method for microsurgical end-to-side anastomoses: technical aspects of use in training and laboratory applications. *J Reconstr Microsurg* 1993;**9**:381.
- Pederson WC, Barwick WJ. Use of the vascular punch in microsurgery. *J Reconstr Microsurg* 1989 Apr;**5**:115–8.
- Hallock GG, Rice DC. Use of a micropunch for arteriotomy in end-to-side anastomosis. *J Reconstr Microsurg* 1996 Jan;**12**:59–62.
- Adams Jr WP, Ansari MS, Hay MT, et al. Patency of different arterial and venous end-to-side microanastomosis techniques in a rat model. *Plast Reconstr Surg* 2000 Jan;**105**:156–61.
- Lazzarini-Robertson AA. Hemodynamic principles and end-to-side vascular anastomoses. *Arch Surg* 1962;**82**:384.
- Tham C, Tan BK, Hong SW, et al. Salvage of the Massively Traumatized Lower Extremity with Sequential Free Flaps. *Plast Reconstr Surg* May 2004;**113**:1746–50.
- Gu H, Chua A, Tan BK, et al. Nonlinear finite element simulation to elucidate the efficacy of slit arteriotomy for end-to-side arterial anastomosis in microsurgery. *J Biomech* 2006;**39**:435–43.
- Kim JT. Two options for perforator flaps in the flank donor site: latissimus dorsi and thoracodorsal perforator flaps. *Plast Reconstr Surg* 2005;**115**:755–63.
- www.microflap.com.