

6

Anatomy of the aging face

Bryan Mendelson and Chin-Ho Wong

SYNOPSIS

- Aging of the face is a multifactorial process that can be explained on an anatomical basis.
- The face is constructed of five basic layers that are bound together by a system of facial retaining ligaments.
- To facilitate the mobility needed for facial expression independent of the basic functions of the face, particularly of mastication, a series of soft tissue spaces are incorporated into the architecture of the face.
- This arrangement, most clearly seen in the scalp, also exists in the rest of the face, although with significant compaction and modifications.
- This chapter will describe, in detail, the five-layered construct of the face, including the spaces and retaining ligaments, and will highlight the relevance of these structures in the aging face.
- In addition, the profound impact of aging of the facial skeleton should be appreciated.
- Understanding these principles will help not only in understanding the aging process but also in designing procedures that are logical and effective in reversing the stigmata of the aging face.

Introduction

Facial aging is a complex process that is the cumulative effect of simultaneous changes of the many components of the face as well as the interaction of these components with each other. An understanding of the anatomical changes associated with aging is required in order to design effective procedures to rejuvenate various aspects of the aging face. Fundamental to understanding these changes is a firm grounding in the principles on which the facial soft tissue layers are constructed.¹ This is important because the pathogenesis of facial aging is explained on an anatomical basis, particularly the variations in the onset and outcome of aging seen in different individuals. Understanding the principles on which the facial soft tissues are constructed is the basis for an accurate and reliable

intraoperative map for the surgeons to safely navigate to the area of interest to correct aging changes. This is most important in addressing the overriding concern, being the course of the facial nerve branches. An anatomical approach to surgical rejuvenation of the face provides the way to obtaining a “natural” result that is lasting and with minimal morbidity.

Regions of the face

The traditional approach to assessing the face is to consider the face in thirds (upper, middle, and lower thirds).² While useful, this approach limits conceptualization, as it is not based on the function of the face. From a functional perspective, the face has an anterior aspect and a lateral aspect. The anterior face is highly evolved beyond the basic survival needs, specifically, for communication and facial expression. In contrast, the lateral face predominantly covers the structures of mastication.³ A vertical line descending from the lateral orbital rim is the approximate division between the anterior and lateral zones of the face. Internally, a series of facial retaining ligaments are strategically located along this line to demarcate the anterior from the lateral face (*Fig. 6.1*). The mimetic muscles of the face are located in the superficial fascia of the anterior face, mostly around the eyes and the mouth. This highly mobile area of the face is designed to allow fine movement and is prone to develop laxity with aging. In contrast, the lateral face is relatively immobile as it overlies the structures to do with mastication, the temporalis, masseter, the parotid gland and its duct, all located deep to the deep fascia. The only superficial muscle in the lateral face is the platysma in the lower third, which extends to the level of the oral commissure.

Importantly, the soft tissues of the anterior face are subdivided into two parts; that which overlies the skeleton and the larger part that comprises the highly specialized sphincters overlying the bony cavities.⁴ Where the soft tissues overlie the orbital and oral cavities they are modified, as there is no deep

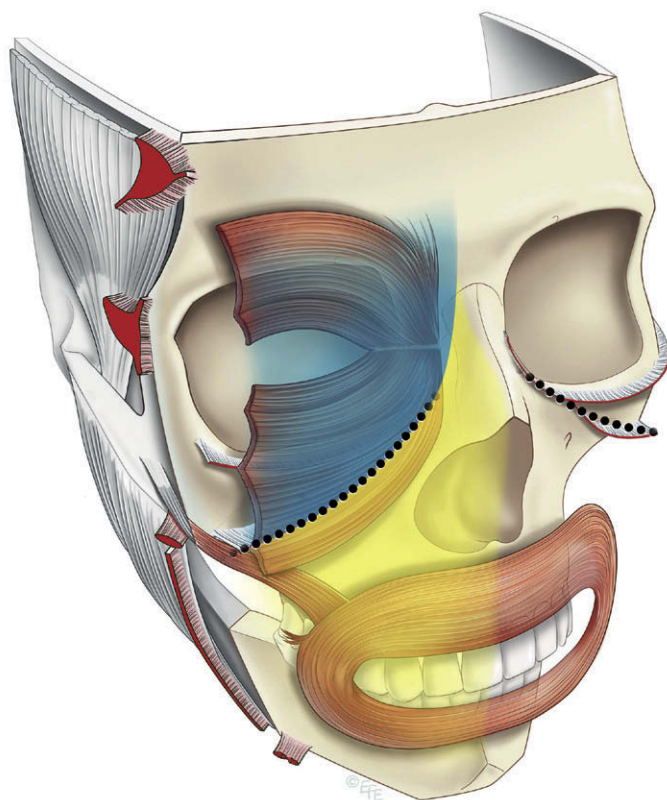


Fig. 6.1 Regions of the face. The mobile anterior face is functionally adapted for facial expressions and is separated from the relatively fixed lateral face (shaded), which overlies masticatory structures. A vertical line of retaining ligaments (red) separates the anterior and lateral face. These ligaments are, from above: temporal, lateral orbital, zygomatic, masseteric, and mandibular ligaments. In the anterior face, the mid-cheek is split obliquely into two separate functional parts by the mid-cheek groove (dotted line) related to two cavities: the periorbital part above (blue) and the perioral part below (yellow). (© Dr Levent Efe, CMI.)

fascial layer for support. Accordingly, support does not come from within the cavity beneath, but from the rim of the cavities. The transitions between these areas, while not seen in youth, become increasingly evident with aging.

Surgical anatomy of the face, SMAS, facial spaces and retaining ligaments

The soft tissue of the face is arranged concentrically into the five basic layers^{5,6}: (1) skin; (2) subcutaneous; (3) musculo-aponeurotic layer; (4) areola tissue; and (5) deep fascia. This five-layered arrangement is most clearly seen in the scalp and forehead as a result of evolutionary expansion of the underlying cranial vault necessary to accommodate the highly developed frontal lobe in humans. Accordingly, the scalp is an excellent place to study the principles of the layered anatomy (**Fig. 6.2**). Layer 4 (the loose areolar tissue) is the layer that allows the superficial fascia (defined as the composite flap of layers 1 through 3) to glide over the deep fascia (layer 5). The simplified anatomy over the scalp gives the basic prototype of layer 4. There are not any structures crossing this plane, which is essentially an avascular potential space. At the boundaries of the scalp along the superior temporal line and

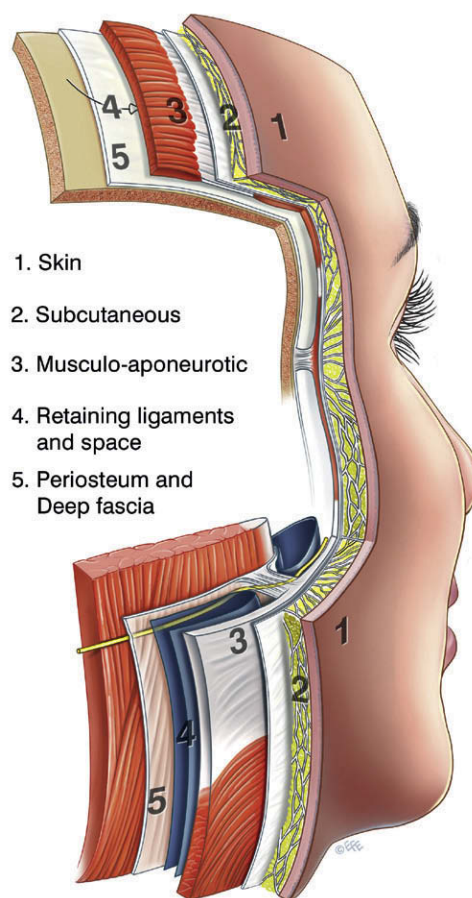


Fig. 6.2 The face is constructed of five basic layers. This five-layered construct is most evident in the scalp but exists in the rest of the face, with significant modification and compaction for functional adaptation. Layer 4 is the most significantly modified layer, with alternating facial soft tissue spaces and retaining ligaments. Facial nerve branches also transition from deep to superficial in association with the retaining ligaments through layer 4. (© Dr Levent Efe, CMI.)

across the supraorbital rim, the scalp and the forehead are firmly anchored by ligamentous attachments. Vital structures, the nerves and vessels are always located in close proximity to the retaining ligaments. In the face proper, while the principles of construction remain the same, there is considerably greater complexity. This is due to the compaction resulting from the absence of forward projection of the midface, as occurs in other species, and the predominance of the orbital and oral cavities that limit the availability of a bony platform for attachment of ligaments and muscles. To secure the superficial fascia to the facial skeleton, a system of retaining ligaments bind the dermis to the skeleton, and the components of this system pass through all layers (**Figs 6.3, 6.4**).^{7,8}

The structure and composition of each of the 5 layers will now be described in turn.

Layer 1: skin

The epidermis is a cell-rich layer composed mainly of differentiating keratinocytes and a smaller number of pigment producing melanocytes and antigen-presenting Langerhans cells. The dermis is the outer layer of the structural superficial fascia and comprises predominantly the extracellular matrix secreted

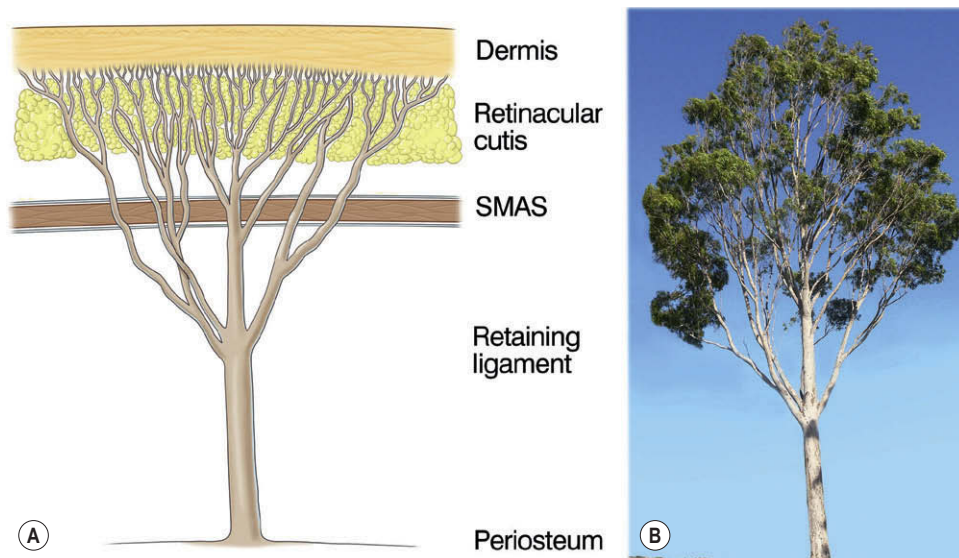


Fig. 6.3 The retaining ligaments of the face can be likened to a tree. The ligaments attach the soft tissues to the facial skeleton or deep muscle fascia, passing through all five layers of the soft tissues. It fans out in a series of branches and inserts into the dermis. At different levels of dissection, it is given different names, such as the retinacular cutis in the subcutaneous layer and ligaments in the subSMAS level. (© Dr Levent Efe, CMI.)

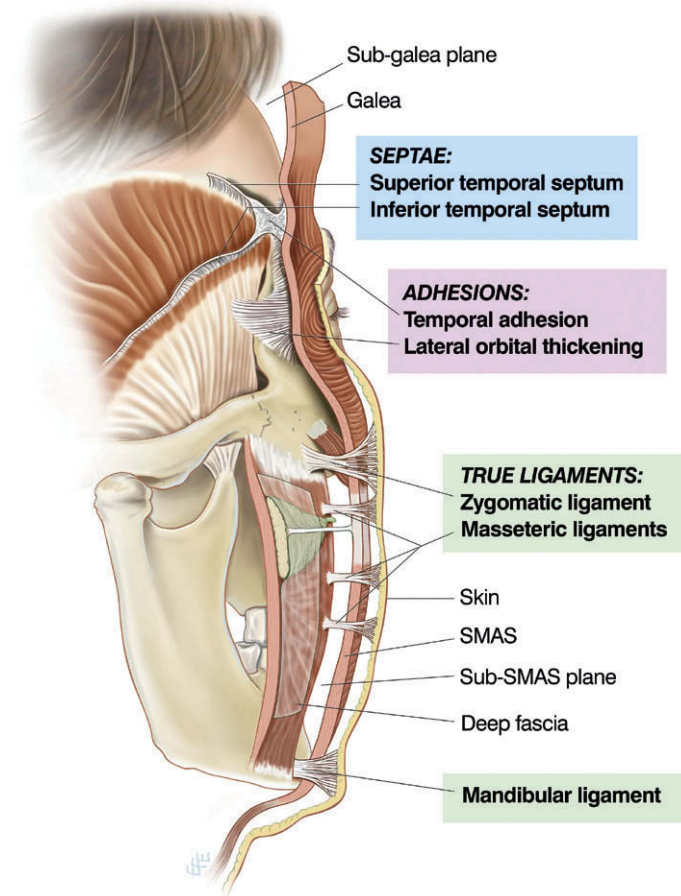


Fig. 6.4 Three morphological forms of retaining ligaments of the face. (© Dr Levent Efe, CMI.)

by fibroblasts. Type I collagen is the most abundant protein. Other collagen types (III, V, VII), elastin, proteoglycans and fibronectins are present in smaller quantities. A rich vascular plexus is an important component of the dermis. The thickness of the dermis relates to its function and tends to be inversely proportionate to its mobility. The dermis is thinnest in the eyelids and thickest over the forehead and the nasal tip.

The thinner the dermis, the more susceptible it is to qualitative deterioration aging changes.

Layer 2: subcutaneous tissue

The subcutaneous layer has two components: the subcutaneous fat, which provides volume, and the fibrous retinacular cutis that binds the dermis to the underlying SMAS.⁹ Of note, the retinacular cutis is the name given to that portion of the retaining ligament that passes through the subcutaneous tissues. The amount, proportion and arrangement of each component vary in different regions of the face. In the scalp, the subcutaneous layer has uniform thickness and consistency of fixation to the overlying dermis. In contrast, in the face proper, the subcutaneous layer has significant variation in thickness and attachments. In specialized areas such as the eyelids and lips, this layer is significantly compacted such that fat may appear non-existent. In other areas, such as the nasolabial segment, it is very thick.⁴ In areas with thick subcutaneous tissue, the retinacular cutis lengthens significantly, predisposing its fibers to weakening and distension with aging. Within the subcutaneous tissue, the overall attachment to the overlying dermis is stronger and denser than the attachment to the underlying SMAS.⁹ This is a result of the tree-like arrangement of the retinacular cutis fibers (*Fig. 6.3*), with fewer but thicker fibers deep as it rises through the SMAS that progressively divide into multiple fine microligaments as they reach the dermis. This explains why it is easier to perform subcutaneous dissection in the deeper subcutaneous level (just on the surface of the underlying SMAS) than more superficially nearer the dermis, as there are fewer retinacular cutis fibers and the subcutaneous fat here does not attach directly to the outer surface of the underlying SMAS.

Furthermore, the retinacular cutis fibers are not uniform across the face, but vary in orientation and density according to the anatomy of the underlying deeper structures. As will be apparent when the anatomy of the underlying Layer 4 is described, at the location of the retaining ligaments, the vertically orientated retinacular cutis fibers are the most dense and are the most effective in supporting for the overlying soft tissues and in so doing, forms boundaries that

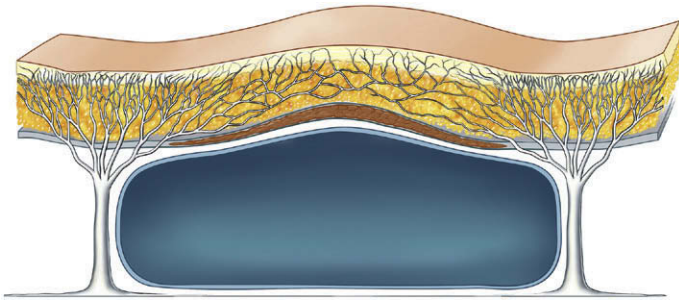


Fig. 6.5 The density and strength of the retinacular cutis fibers in the subcutaneous layer varies in different areas of the face. Where it overlies the retaining ligaments, the fibers are denser and oriented more vertically. In these areas, sharp release is usually necessary to raise a subcutaneous flap. In contrast, in areas overlying a space, the fibers are less dense and oriented more horizontally. Here, it is relatively easy to elevate a subcutaneous facelift flap. (© Dr Levent Efe, CMI.)

compartmentalize the subcutaneous fat. These areas, such as the so-called McGregor's patch over the body of the zygoma, often require sharp release to mobilize. In between these retaining ligaments in layer 4 are located the soft tissue spaces of the face, that facilitate the mobility of the superficial fascia over the deep fascia. Where the subcutaneous fat overlies a space, the retinacular fibers are less dense and orientated more horizontally, as a result of which, the tissues tend to separate with relative ease, often with just simple blunt finger dissection (**Fig. 6.5**). This variation in the density and orientation of the retinacular cutis fibers in the subcutaneous fat is the anatomical basis for the compartmentalization of the subcutaneous fat into discrete compartments, described in detail in **Chapter 11.1**.^{10,11}

Layer 3: musculo-aponeurotic layer

The muscles of facial expression are unique and fundamentally different from skeletal muscles beneath the deep fascia because they are situated within the superficial fascia and they move the soft tissues of which they are a part. All muscles of facial expression have either all or the majority of their course within layer 3 and they are predominantly located over and around the orbital and oral cavities. In the prototype scalp, the occipital-frontalis moves the overlying soft tissue of the forehead, while its undersurface glides over the subaponeurotic space (layer 4). Layer 3 is continuous over the entire face, although for descriptive purposes, different names are given to certain parts according to the superficial muscle within. It is called the galea over the scalp, the temporo-parietal (superficial temporal) fascia over the temple, the orbicularis fascia in the periorbital region, the superficial musculoaponeurotic system (SMAS) over the mid- and lower face and platysma in the neck.^{5,12}

Within layer 3, the facial muscles themselves have a layered configuration, with the broad, flat muscles forming the superficial layer that covers the anterior aspect of the face. The frontalis covers the upper, orbicularis oculi, the middle and the platysma, and lower thirds, respectively. The muscles of this layer have minimal direct attachment to the bone, stabilized to the skeleton at their periphery indirectly by the vertically orientated retaining ligaments as noted earlier. The frontalis is fixed along the superior temporal line by the superior temporal septum, the orbicularis oculi laterally by the

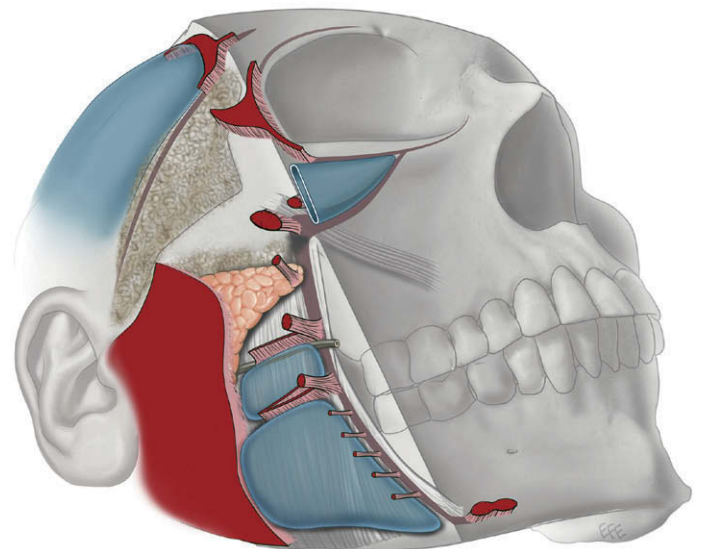


Fig. 6.6 Topographical anatomy of layer 4 over the lateral face. Spaces (blue), ligaments (red) and the areas of important anatomy (stippled). The largest area of ligamentous attachment, the platysma-auricular fascia (PAF), dominates the posterior part of level 4 at the least mobile part of the face. The lateral face transitions into the anterior face at the vertical line of retaining ligaments. Immediately above and below the arch of the zygoma are the triangular-shaped areas that contain the important anatomy proceeding from the lateral into the anterior face. (© Dr Levent Efe, CMI.)

lateral orbital thickening and the main zygomatic ligament at its inferolateral border and the platysma at its upper border by the lower masseteric ligament. The deeper muscles in layer 3 provide greater functional control of the sphincters over the bony cavities. For the upper third, these are the corrugators and procerus, and around the oral cavity, the elevators (zygomaticus major and minor, levator labii superioris, *levator anguli oris*), and the depressors (*depressor anguli oris*, *depressor labii inferioris*) around the oral sphincter and the mentalis.

Layer 4

Layer 4 is the plane in which dissection is performed in subSMAS facelifts. It is an area of significant complexity and contains the following structures: (1) soft tissue spaces; (2) retaining ligaments; (3) deep layers of the intrinsic muscles passing from their bone attachment to their more superficial soft tissue origin; and (4) facial nerve branches, passing from deep to superficial. Functionally, a series of soft tissue spaces exist in layer 4 to allow independent movement of the peri-orbital and perioral muscle of facial expressions over the deep fascia responsible for mastication directly beneath the muscles of facial expression.¹³ The retaining ligaments of the face are strategically placed within the boundaries between the soft tissue spaces and functions to reinforce the boundaries (**Fig. 6.6**). In the lateral face, immediately in front of the ear, extending 25–30 mm forward of the ear cartilage to the posterior border of the platysma, is a diffuse area of ligamentous attachment, described by Furnas as the platysma auricular fascia (PAF).⁷ As no facial expression occurs here, the dermis, subcutaneous tissue, SMAS and the underlying parotid capsule (layers 1–5) are bound together as an area of retaining ligament. Layer 4 is reduced to a layer of fusion here, without a soft tissue space. The ligamentous character of this immobile

area makes it surgically useful for suture fixation. Furnas had originally described the lower part of the PAF, the platysma auricular ligament,⁷ also named by Stuzin and colleagues, the parotid cutaneous ligament⁵ and this ligament was subsequently named the tympanoparotid fascia.¹⁴ The part of the PAF immediately in front of the lower tragus has been labeled, Lore's fascia.¹⁴

In contrast, in the anterior face where there is considerable movement over and around the bony cavities, the ligaments are significantly compacted and arranged around the edges of the bony cavities. These boundaries provide the last position where there is underlying deep fascia for the mobile shutters of the lids and lips to be supported. Importantly for the surgeon, the retaining ligaments also act as transition points for the facial nerve branches to pass from deep to superficial, on their way to innervate their target muscles.

Soft tissue spaces of the face are in two forms: (1) those overlying bony cavities, such as the preseptal space of the eyelid over the orbit and the vestibule of the oral cavity, under the lips and the lower nasolabial segment of the cheek and (2) those overlying the bone, where soft tissue spaces allow the overlying superficial fascia to glide freely over the bone.

Layer 5

The deep fascia, the deepest soft tissue layer of the face, is formed by the periosteum where it overlies bone. Over the lateral face, where the muscle of mastication (temporalis and masseter) overlie the bone, the deep fascia is instead the fascial covering of the muscles, the deep temporal fascia above the zygomatic arch, and masseteric fascia below the arch. The parotid fascia is also part of the deep fascia. The investing deep cervical fascia is the corresponding layer in the neck where it covers the supraomohyoid muscles and splits to form the submandibular space that contains the submandibular gland. The deep fascia, although thin, is tough and unyielding and gives attachment to the retaining ligaments of the face. In the mobile shutters over the bony cavities, the deep fascia is absent, being replaced by a mobile lining derived from the cavities, that of the conjunctiva or oral mucosa.

Anatomy over the cavities in the skeleton

The general pattern of the five-layered anatomy is modified where the soft tissues overlie the orbital, oral and nasal cavities over the anterior face (Fig. 6.7). Only the outer three layers of the composite continue from the periphery as the soft tissue over the cavities. The SMAS layer within this composite includes the sphincteric orbicularis muscles that extend right to the free edge of the soft tissue aperture of the eyelids and lips. The retaining ligaments, which are such a key feature of the five-layered anatomy, are not present over the cavities. There are thus anatomical variations associated with these functional transitions from the relative stability of the "fixed" areas to the high mobility of the soft tissue shutters over the cavities. At the transition, to support the shutters, the retaining ligaments are condensed along the bony orbital rim (Fig. 6.8). This is the anatomical basis for the periorbital ligament around the orbit, of which the lower lid part is the orbicularis

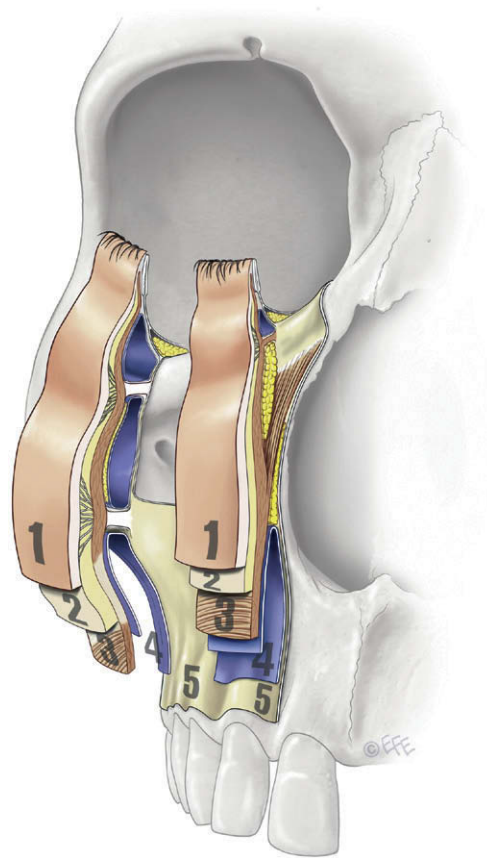


Fig. 6.7 The anatomy over the skeleton and over bony cavities (1–5), showing the relationship of the soft tissue spaces to bony cavity spaces. (© Dr Levent Efe, CMI.)

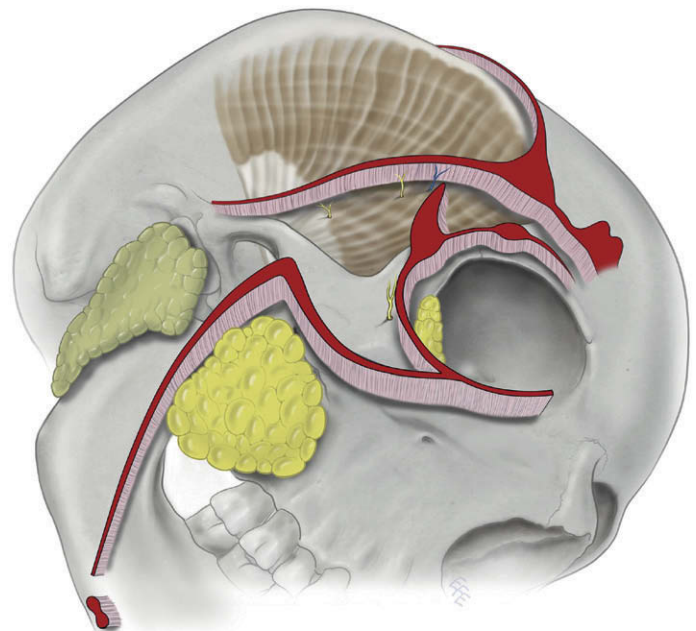


Fig. 6.8 The system of retaining ligaments situated around the bony cavities stabilizes the soft tissue over the cavities. (© Dr Levent Efe, CMI.)

retaining ligament, which stabilizes the orbicularis oculi to the orbital rim periosteum. Around the oral cavity where the boundary is less distinct, the ligaments arise mainly from the platform of the body of the zygoma, and from the deep fascia over the masseter.¹⁵⁻¹⁷

The deeper component of the eyelid and lips are derived from the origin of the cavity and are not an extension of the facial soft tissues. In the eyelid, the deeper lid muscles with their related aponeurosis (levator and capsulopalpebral fasciae) and fat are retained by the fascial system of the septum orbitale. The free edges of the upper and lower eyelids obtain their ligamentous support from the tarsal plates, with their canthal tendon attachments to the medial and lateral orbital rims. In the pretarsal area, the superficial and deep lid structures, the anterior and posterior lamellae, merge. But between the pretarsal area of the lid and the orbital rim the lamellae remain quite separate, i.e., the preseptal orbicularis does not have an attachment to the septum orbitale. This is the anatomical basis for the, surgically significant, preseptal space of the lower lid. In the upper lid, there is not an equivalent space as the submuscular fat pad over the superior orbital rim continues on the outer surface of the septum orbitale where it is adherent to the overlying fascia on the underside of the orbicularis almost down to where the levator crosses into the orbicularis.

The extent of the vestibule of the oral cavity covering the maxilla and the mandible has a major impact on the susceptibility to aging of the overlying soft tissue. The skeleton underlying the space is not available to provide ligamentous attachment for support of the soft tissues that cover this large area. The extreme mobility of the lip and adjacent part of the cheek renders it susceptible to aging changes and the indication for a lower facelift is largely to correct aging changes in this unsupported tissue.

Facial spaces

A large part of the subSMAS layer 4 consists of soft tissue “spaces.” These spaces have defined boundaries that are strategically reinforced by retaining ligaments.¹⁸ Significantly, these areas are by definition anatomically “safe spaces” to dissect, as no structures cross within and all branches of the facial nerve are outside these spaces. As the roof of each space is the least supported part, it is more prone to developing laxity with aging, compared with the ligament-reinforced boundaries. This differential laxity accounts for much of the characteristic changes that occur with aging of the face. Once a space has been surgically defined to its boundaries, the retaining ligaments in the boundary can then be precisely released under direct vision to achieve the desired mobilization, while preserving the vital structures closely associated with the ligaments. A brief description of surgically significant facial soft tissue spaces is given below.

Upper temporal space

The upper temporal space separates the temporoparietal fascia (superficial temporal fascia) from the (deep) temporal fascia and is separated from the forehead by the superior temporal septum (STS) along the superior temporal line (**Fig. 6.9**). Anteroinferiorly, the upper temporal space is separated from

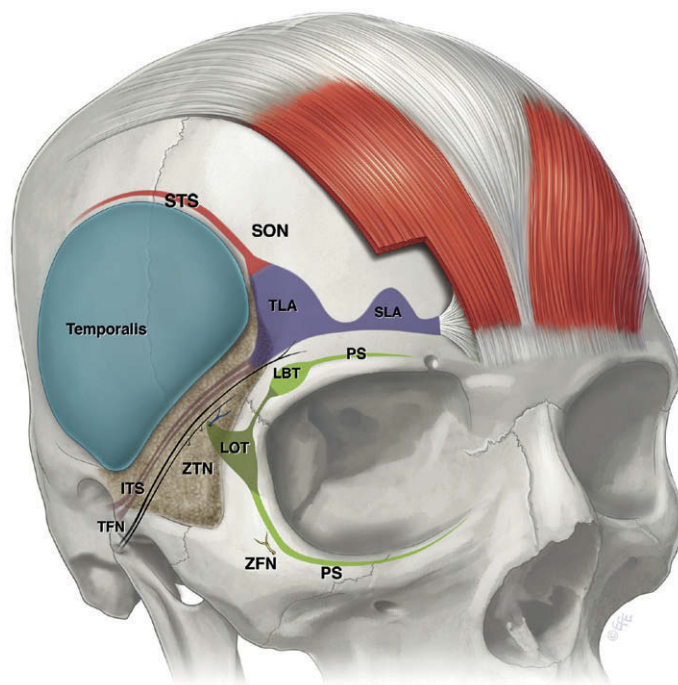


Fig. 6.9 The upper temporal space and the retaining ligaments of the temple. The boundaries of the space are the superior temporal septum (STS) and the inferior temporal septum (ITS), which are extensions of the temporal ligament adhesion (TLA). No structures cross the temporal space. The TLA continues medially as the supraorbital ligamentous adhesion (SLA). Inferior to the temporal space is the triangular-shaped area of important anatomy (stippled). Crossing level 4 in this area are the medial and lateral branches of the zygomatic temporal nerve (ZTN) and the sentinel vein. The temporal branches of the facial nerve (TFN) course on the underside of the temporal-parietal fascia over the area immediately inferior to the inferior temporal septum. The periorbital septum (PS, green) is on the orbital rim at the boundary of the orbital cavity. The lateral orbital thickening (LOT) and the lateral row thickening (LBT) are parts of the periorbital septum. SON, supraorbital nerve; ZFN, zygomaticofacial nerve. (© Dr Levent Efe, CMI.)

the lower triangular shaped temporal area that contains important anatomy, by the inferior temporal septum (ITS). These septi merge at the triangular-shaped zone of adhesion called the temporal (orbital) ligament.¹⁵ The upper temporal space provides safe surgical access to the lateral brow and upper mid-cheek. The space can be readily opened by blunt dissection to its boundaries. Once identified, the boundaries are then released by precise sharp dissection. The superior temporal septum can be released sharply, taking care only to preserve the lateral (deep) branch of the supraorbital nerve, which runs parallel to the septum about 0.5 cm medial to it.¹⁹ The inferior temporal septum provides a marker to the important anatomy here as the temporal branches of the facial nerve are located parallel to and immediately inferior to this septum. To release the inferior temporal septum, the roof of the space is gently lifted off the deep temporal fascia floor, which three-dimensionalizes the septum in preparation for its gentle release at the level of the floor, bearing in mind the frontal branches are located under the roof of the lower temporal area where they travel in the ceiling within the layer of fat suspended on the underside of the temporoparietal fascia. Once released, the sentinel vein comes into view. The sentinel vein is not a good landmark for locating the temporal branches as they course cephalad to the vein, that is, inferior to the inferior temporal septum. This anatomy is also reviewed in **Chapter 7**.

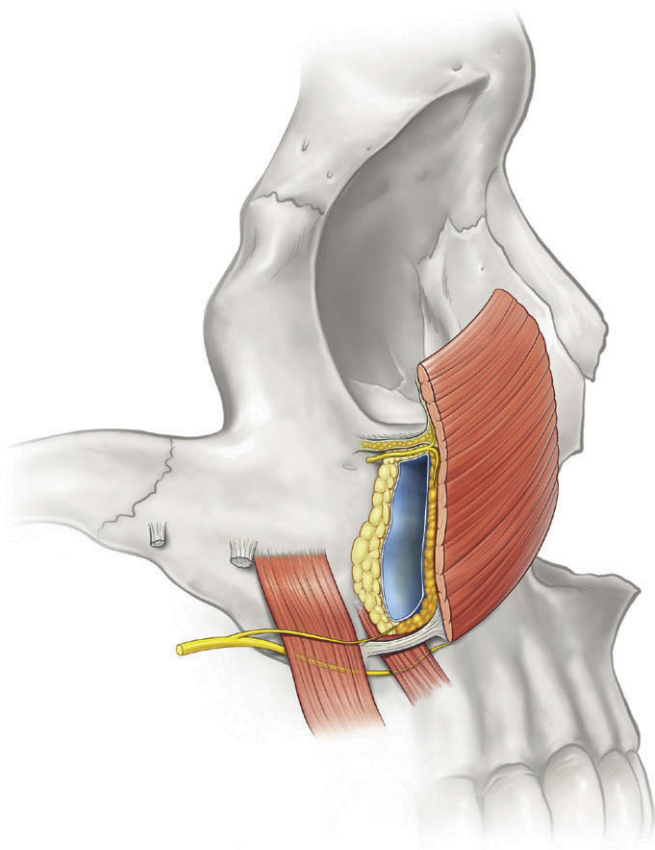


Fig. 6.10 The prezygomatic space overlies the body of the zygoma. The origin of the zygomatic muscles extends under the floor. The roof is formed by the orbicularis oculi line by the suborbicularis oculi fat (SOOF). The upper ligamentous border formed by the orbicularis retaining ligament is not as strong as the zygomatic ligament reinforced lower border. (© Dr Levent Efe, CMI.)

Prezygomatic space

This triangular-shaped space overlies the body of the zygoma, its floor covering the origins of the zygomatic muscles. The space allows the independent displacement of the orbicularis oculi (pars orbitale) in the roof from the zygomatic muscles under the floor. Contraction of the overlying orbicularis elevates the prezygomatic soft tissues, which results in zygomatic smile lines (below the crow's feet) (**Fig. 6.10**). With the laxity of aging the roof of the space rests at a lower level than in youth. As a result, there is a now a greater amplitude of movement on orbicularis contraction that has the effect of exaggerating the zygomatic lines with aging.^{13,16} This aging of the prezygomatic space, with bulging over its roof accentuated by its well-supported boundaries, is the anatomical basis for the clinical entity variously described as malar mounds, bags or malar crescent. These deformities indicate the presence of significant laxity and the treatment is directed to tightening the laxity of the roof and upper ligamentous boundary.

Premasseter space

This space overlies the lower half of the masseter and is analogous to the temporal space, in that it overlies the deep fascia of a muscle of mastication (**Fig. 6.11**).¹⁸ This gliding soft tissue

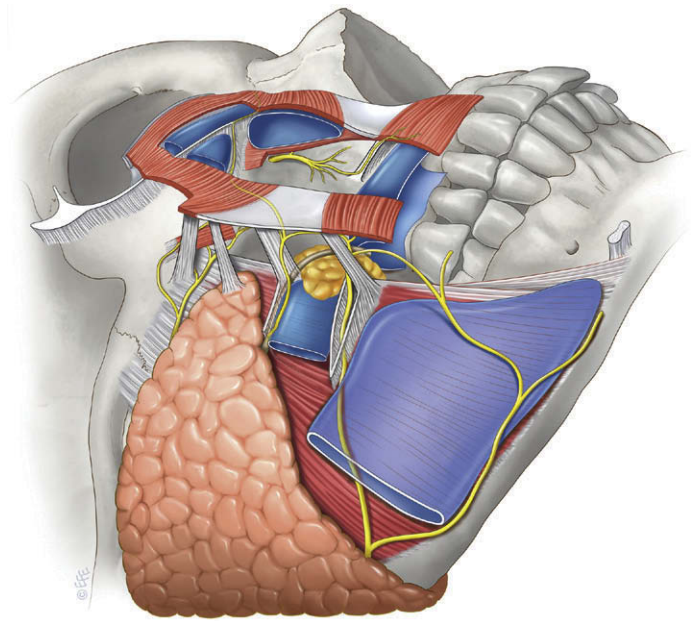


Fig. 6.11 The rhomboidal-shaped premasseter space overlies the lower half of the masseter. The roof of the space is formed by the platysma. The posterior border is defined by the anterior edge of the strong PAF and the anterior border is reinforced by the masseteric ligaments near the anterior edge of the masseter. The inferior boundary is mesenteric-like and does not contain any ligament. Weakness of attachment of the platysma roof at the inferior boundary leads to the formation of the jowl directly behind the strong mandibular ligament. The buccal space containing the buccal fat is anterior to the upper masseteric ligaments. All facial nerve branches course around and outside the space. The surgically important mandibular branch, after leaving the fixed PAF, courses under the inferior boundary of the space, then rises onto the highly mobile outer surface of the mesenteric inferior border before reaching the mandibular ligament. (© Dr Levent Efe, CMI.)

plane allows opening of the jaw without restriction and avoids excessive distortion of the overlying soft tissues. The roof of this space is formed by the platysma. The lower premasseter space has profound clinical significance, as it is the anatomical basis for the development of jowls with aging. Laxity in the roof of the space, particularly where it has a weakened attachment to the anterior masseter by the masseteric ligaments and its inferior boundary where there is no ligament, manifests as the labiomandibular fold and jowl, respectively. The relatively stable fixation at the anteroinferior corner of the premasseter space provided by the mandibular ligament accounts for the dimple that is commonly seen separating the labiomandibular fold above and the jowl below.

Buccal space

This is one of the deep facial spaces, being, like the sub-mandibular space (which contains the submandibular gland), deep to the deep fascia (layer 5). The buccal space is located in the anterior face, medial to the anterior border of the masseter above the level of the oral commissure in youth.^{20,21} The space and its contents, the buccal fat, facilitates movement of the overlying nasolabial segment of the mid-cheek as well as buffering this area from excessive motion from jaw movement. Aging and attrition of the boundaries, particularly of the masseteric ligaments inferiorly result in the platysma

being less firmly bound to the masseter. This allows the space to enlarge and also allows the buccal fat to prolapse inferiorly, below the level of the commissure into the lower face. As the buccal fat comes to overlie the anterior border of the lower masseter it results in increased prominence of the labiomandibular fold and jowl.

Facial nerve branches

The danger zone for facial nerve injury has been well described in the literature, but is of limited value to the surgeon due to the two-dimensional perspective that gives the expected course of the nerve relative to surface landmarks.^{22–24} Confidence when approaching the nerve surgically comes from an understanding the three-dimensional course of the nerve relative to the layered anatomy as described above and visually identifying the nerves in relation to defined landmarks (**Fig. 6.12**). The facial nerve branches exit the parotid gland and remain deep to layer 5 in the lateral face. As they approach the anterior face, the branches traverse layer 4 to reach the underside of mimetic muscles of the face. It is at these transition points across layer 4 that the nerves are at greatest risk of injury.^{1,25} The transitions occur at predictable locations, in close association with retaining ligaments that provide stability and protection for the nerves. The surgical release of these ligaments to gain the needed mobility should be performed with extreme care on account of the proximity of the nerves.

The surface marking of the temporal branch of the facial nerve is along the Pitanguy line, from a point 0.5 cm below the tragus to a point 1.5 cm lateral to the supraorbital rim.^{26,27} It is traditional teaching that once the temporal branch exits the parotid, it immediately runs superficially from the deep fascia and comes to lie just deep to the SMAS as it crosses the arch of the zygoma.^{5,28,29} Because of its superficial location,

surgical transection of the SMAS here, so-called high SMAS transection (i.e., at or above the arch) has been generally discouraged. It is now apparent that the nerve is deeper than was previously thought as it crosses the zygomatic arch.³⁰ A histological study confirmed that the frontal branches are in transition from where they exit the parotid below the zygomatic arch, to where they enter the underside of the temporoparietal fascia some 2 cm above the arch. They course in a tissue layer (layer 4), just deep to the temporoparietal fascia (layer 3) and immediately superficial to the periosteum and above that, the temporalis fascia (layer 5), all along protected by a fascial, fatty layer, which is an upward prolongation of the parotid-masseteric fascia and named the parotid-temporal fascia.²⁷ Another study noted the temporal branch to transition to under the temporoparietal fascia (layer 3) at a distance of 1.5–3 cm above the zygomatic arch.³¹ The temporal branch completes the transition to the underside of the temporoparietal fascia well before the nerve crosses cephalad to the sentinel vein.¹⁵ Accordingly, once the sentinel vein is visualized from the temporal aspect, the temporal branches would already be located in the roof of the lower temporal area.

The zygomatic branch exits the parotid gland deep to the deep fascia just below the zygoma and cephalad to the parotid duct. It travels horizontally on the masseter with the transverse facial artery.^{32,33} At the lateral border of the origin of zygomaticus major muscle is the substantive zygomatic retaining ligament (that attaches to the body of the zygoma). At the lateral border of zygomaticus major, after a branch is given off to supply the orbicularis oculi, entering the muscle at its inferolateral corner, the zygomatic nerve continues medially and then transitions to the underside of the muscles it innervates zygomaticus major and minor, and supplies them from the deep aspect in close association with the zygomatic ligaments. Careful dissection by vertical spreading of the scissors is crucial to avoid damaging this branch here.^{16,24,34}

The upper buccal trunk exits the parotid, about in line with, but superficial to, the parotid duct and continues deep to the investing masseter fascia. Approaching the anterior edge of the masseter, this branch leaves the floor under the masseter fascia in close association with the upper key masseteric ligament.^{5,35} The lower buccal trunk leaves the parotid lower down, at about the level of the earlobe and remains under the masseter fascia as it crosses under the floor of the premasseter space. Similarly, upon approaching the anterior edge of the masseter, in the upper membranous boundary of the premasseter space, the lower buccal trunk transitions from deep to gain the underside of the SMAS in close association with the upper surface of the lower key masseteric ligament.¹⁸ After the nerves reach level 3, the zygomatic, upper and lower buccal trunks, and mandibular branch connect with each other before continuing their course to innervate the mimetic muscles. This accounts for the overlap in muscles innervated by these nerves.

The temporal and mandibular branches are the most significant in terms of surgical risks because of the lack of cross innervation of their target muscle. The marginal mandibular nerve is at risk where it is fixed by its close association with the retaining ligaments. Early in its course, around the angle of the mandible, this is within the PAF, and then well anteriorly by the mandibular ligament. Over most of its course, the mandibular branch is mobile, being in relation to the inferior

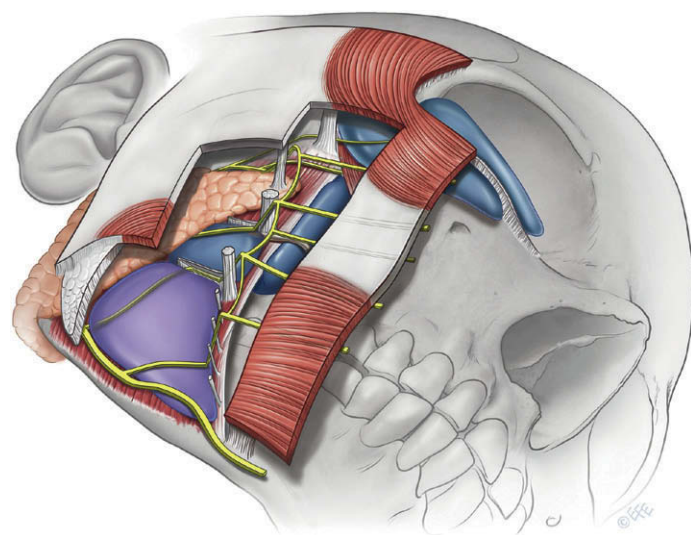


Fig. 6.12 The relationship between facial nerve branches, spaces and retaining ligaments. The nerves stay deep to and outside of the spaces at all times in the lateral face. In the boundary between the lateral and anterior face, the facial nerve branches transition from under layer 5 to enter layer 3, always in close association with the retaining ligaments of the face. (© Dr Levent Efe, CMI.)

boundary of the premasseter space. It is not necessary to dissect in the vicinity of the nerve because of the inherent mobility of the platysma where it overlies the jaw and sub-mandibular area. The mobility of the nerve as it travels within the inferior membranous boundary of the lower premasseter space accounts for the reported variability of the location of this part of its course (occasionally below the mandible).³⁶⁻³⁸

Aging changes of the face

The youthful face has the general appearance of high rounded fullness, while the aging process is characterized by a look of depletion and sagging, suggestive of tiredness. Changes with aging occur at every level of the facial anatomy, starting with the facial skeleton. A key unresolved question is how much of the change at each level is intrinsic aging and how much is secondary to the changes from adjacent layers. This is not easy to quantitate due to the difficulties of measurement of a single layer in the context of the complicated and interrelated layered structure.

Current understanding of the aging process remains largely empirical, given that it is based on the effectiveness of treatments designed to satisfy the requirements of patients for a younger appearance. Historically, stretching of loose facial skin (traditional facelift), removal of apparent tissue excess (traditional blepharoplasty), tightening the dermis and evening the complexion (early phenol peels and CO₂ laser resurfacing) and, in recent years, soft tissue volume augmentation (lipofilling and soft tissue fillers) have all had a positive impact on rejuvenating appearance. The success of each is attributed to having reversed a cause of facial aging. Yet, when each of these modalities is continued as the sole treatment, to further reverse the aging appearance, the results tend to be bizarre, leading to the conclusion that multimodal therapy is required to further reverse, what must be, multiple components of the aging process.

An understanding of the changes that occur in the layered anatomy forms the basis for logical treatment. Changes of the skin are readily observable and changes in the skeleton effecting layer 5 can also be observed radiologically. Because the changes within the superficial fascia (layers 2 and 3) are not directly measurable, empiricism has remained prevalent. A correlation of the surface anatomy changes of aging with the anatomy of layers 2, 3, and 4 indicates that bulging occurs over the roof of soft tissue spaces, which stand out in contrast to the absence of bulging of the adjacent cutaneous grooves. The grooves reflect the restriction imposed by the dermal insertions of the retaining ligaments at the boundaries of the spaces. The degree to which the bulging reflects true elongation from primary tissue degeneration and laxity and how much it is 'apparent' laxity secondary to loss of volume (skeletal and soft tissue) remains unanswered.

Skin

Skin aging is influenced by genetics, environmental exposure, hormonal changes and metabolic processes.³⁹⁻⁴¹ With aging, the supple skin of youth becomes thinned and flattened, with loss of elasticity and architectural regularity. Atrophy of the extracellular matrix is reflected by the decreased number of

fibroblasts and decreased levels of collagen (especially types I and III) and elastin in the dermis. While chronological skin aging and photo-aging can be readily distinguished and considered separate entities, both share important molecular features, that of altered signal transduction that promote matrix-metalloproteinase (MMP) expression, decreased pro-collagen synthesis and connective tissue damage. Oxidative stress is considered of primary importance in driving the aging process, resulting in increased hydrogen peroxide and other reactive oxygen species (ROS) and decreased anti-oxidant enzymes.^{42,43} These changes result in gene and protein structure alterations. Other environmental factors notably smoking accelerates skin aging, by between 10 and 20 years.⁴⁴ Increased collagenase and decreased skin circulation has been suggested as possible mechanisms. The muscles of facial expression flex the skin in a specific pattern. As the underlying collagen weakens and the skin thins, the dermis loses its capacity to resist the constant force of the muscles and these lines become etched in the skin and ultimately even at rest.

Subcutaneous tissue

The fibrous and fat components in the subcutaneous tissue are not a uniform but arranged in discrete compartments.¹⁰ Over specific sites, due to the prominence of the subcutaneous fat it has been given specific names such as the malar fat pad and nasolabial fat. The boundary of these subcutaneous compartments corresponds to the location of the retaining ligaments, which pass superficially to insert into the dermis. In youth, transition between compartments is smooth and non-discernible. With aging, a series of concavities and convexities develop which separates these compartments. These changes have been attributed to a number of causes including fat descent, selective atrophy and hypertrophy and attenuation of the retaining ligaments that causes fat compartments mal-positioning.^{9,10,45,46} It is now apparent that fat descends minimally with aging.⁴⁷ As noted the subcutaneous fat is not a confluent layer that can descend with aging. Distinct compartmentalization by the retaining ligaments holds the fat in its relative positions.

Muscle aging

Skeletal muscles, in general, have been noted to atrophy up to 50% with age.⁴⁸ This may be applicable to the muscle of mastication such as the temporalis and masseter (compounded by the decreased demand and deterioration of the dentition with aging) although no specific study on the effect of aging on these muscles has been done to date. The mimetic muscle of the face, in contrast to skeletal muscles, may not undergo the same degree of degeneration with aging because of their constant use with facial expression. The orbicularis oculi has been noted to remain histologically unchanged with no loss of muscle fibers aging.⁴⁹ The upper lip elevators, zygomaticus major and levator labii superioris were also noted to remained unchanged with aging, based on magnetic resonance imaging (MRI) of their length, thickness and volume.⁴⁵ In contrast, the upper lip orbicularis atrophies with aging, with decreased muscle thickness, smaller muscle fascicles and increase in surrounding epimysium.⁵⁰

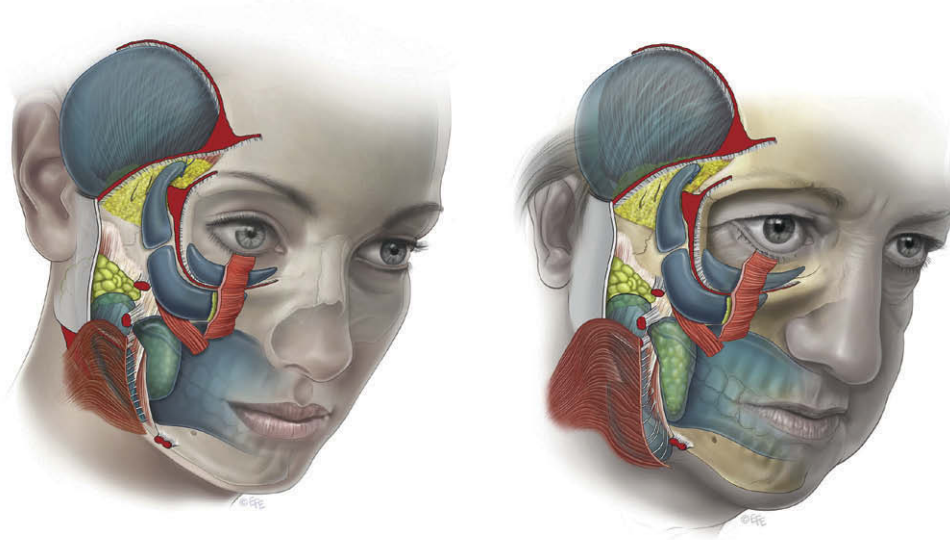


Fig. 6.13 In youth, the spaces are tight. The retaining ligaments are stout and the transition between spaces is not discernible. With aging, spaces expand to a greater extent than the laxity that develops in ligaments within their boundaries, resulting in bulges between areas of relative fixations. These spaces open with relative ease with blunt dissection. (© Dr Levent Efe, CMI.)

Facial spaces and retaining ligaments

The multi-linked fibrous system attenuates with aging, with decreasing strength of the ligaments and increasing laxity. The spaces expand with aging as well, to a greater extent than the laxity that develop in the ligaments within their boundaries, resulting in bulges between areas of relative fixations.¹⁸ Accordingly, the spaces dissect easily in older patients, and the boundaries widen as the ligaments weaken.¹³ In young people, the spaces are more potential than real and do not open quite so easily with blunt dissection (**Fig. 6.13**).

Bone changes

The facial skeleton changes dramatically with aging (**Fig. 6.14**) and this has a profound impact on the appearance of the face with aging (**Fig. 6.15**). At birth, the facial skeleton is underdeveloped and rudimentary. This explains why infants and toddlers often transiently have distinct mid-cheek segments (despite excellent tissue quality), which disappear as they grow older with the expansion of the mid-cheek skeleton.⁵¹ Peak skeletal projection is probably attained in early adulthood. Thereafter, while certain areas continue to expand,^{4,52–55} selective areas of the facial skeleton undergoes significant resorption. Areas with strong predisposition to resorption include the superomedial and inferolateral aspects of the orbital rim, the midface skeleton, particularly that part contributed by the maxilla including the pyriform area of the nose and also the prejowl area of the mandible.^{56–64} The resultant deficiencies in the skeletal foundation have a significant effect on the overlying soft tissues. In the mid-cheek in particular, retrusion of the maxilla causes increased prominence of the tear-trough and the nasolabial folds.⁵⁹ The retrusion of the facial skeleton causes the origin of the multi-linked fibrous retaining ligaments to be displaced posteriorly. This pulls the skin inwards, exaggerating the concavity between the areas of relative convexity that develop with aging. Retrusion of the mid-cheek with loss of projection gives the visual impression

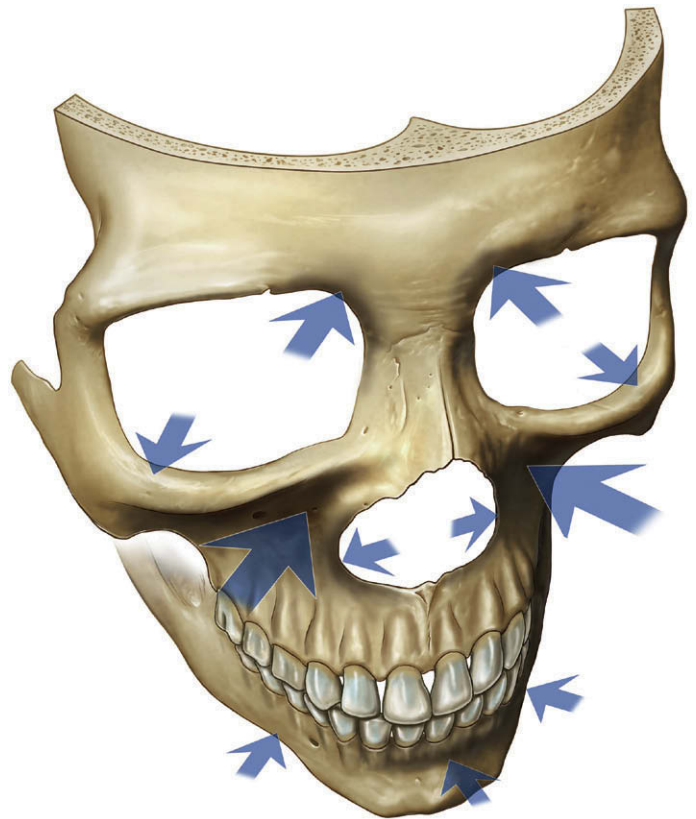


Fig. 6.14 Arrows indicate the areas of the craniofacial skeleton that are susceptible to resorption with aging. (© Dr Levent Efe, CMI.)

of tissue descent with aging. Some patients have a congenitally weak or inadequate skeletal structure. In such cases, the skeleton may be the primary cause of the manifestations of premature aging. Accordingly, patients who suffer premature facial aging, a weakness of the relevant part of the underlying skeleton is immediately suspect and should be addressed in order to obtain better aesthetic results.

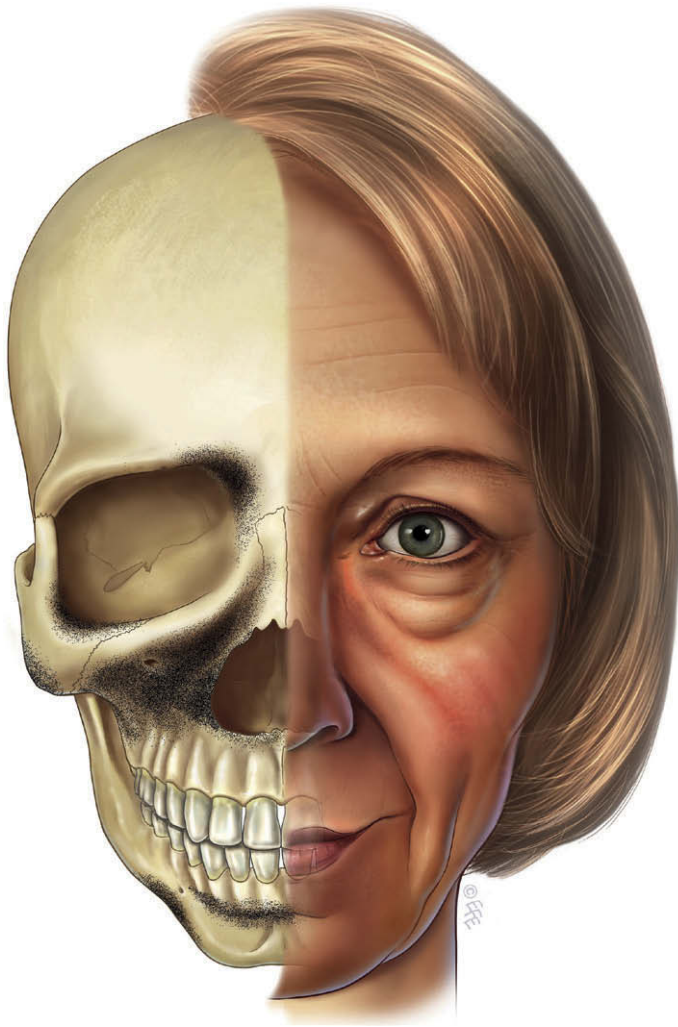


Fig. 6.15 The darker areas denote areas of greatest bone loss. Note how the stigmata of aging as manifested by the facial soft tissues correspond to the areas of weakened skeletal support due to bone loss. (© Dr Levent Efe, CMI.)

Regional changes observed with the aging face

Temple and forehead

The skin of the temple differs from that of the forehead, being thinner and less firmly supported to the underlying layers. The loose attachment reflects the underlying temporal space, which is extensive, and the nature of the surrounding temporal ligaments that are septal like and do not continue through the thin, loose subcutaneous layer over the temple to fix to the dermis as do facial ligaments elsewhere. This explains why deep layer procedures in the temple are not as effective in toning the overlying skin as they are, for example, in the cheek.

Corrugator muscle contraction is associated with the emotional states of grief and sadness.⁶⁵ The transverse head of corrugator supercilii moves the eyebrow medially and produce vertical glabella lines. The oblique head of the corrugator, the depressor supercilii and the medial fibers of the

orbicularis oculi act in concert to depress the medial brow and produce oblique glabella frown lines. The procerus, also a brow depressor causes transverse nasal skin lines. Laterally, the action of the lateral fibers of the orbicularis oculi with the transverse head of the corrugator supercilii promotes lateral brow ptosis. The ptosis of the lateral brow together and to a lesser extent, the laxity of the skin with aging produces a pseudoexcess of the upper eyelid skin. Frontalis muscle hypertonicity from lateral brow skin hooding and its reaction to the action of antagonistic muscles (corrugator supercilii, orbicularis oculi and procerus) results in the development of transverse forehead skin lines.^{18,65} The medial brow in contrast, seldom descends with aging and in fact, may rise.^{66,67} The mechanism responsible for this includes the chronic activation of the frontalis muscle. This may either be to elevate the brow/eyelid complex associated with clinical or subclinical levator system weakness or to relieve visual field obstruction due to excess lateral upper eyelid skin.⁶⁵ Anatomically, the frontalis muscle ends at approximately the temporal fusion line (superior temporal septum). Lateral to this, there is no upward vector to counteract the downward pull of brow depressors and gravity on the lateral brow. This may explain why descent preferentially occurs at the lateral brow.

The mid-cheek

The mid-cheek is the anterior part of the midface.⁴ It is triangular in shape and bounded superiorly by the pretarsal part of the lower eyelid, medially by the side of the nose and the nasolabial groove below, and laterally around the lateral cheek where the arch of the zygoma meets the body. A smooth rounded mid-cheek is a powerful image of youth and gives a certain freshness to the face. With aging, the three mid-cheek segments become clearly discernible, as they become separated by the three cutaneous grooves of the mid-cheek; the nasojugal, palpebromalar and mid-cheek grooves.⁴ This 'segmentation' of the mid-cheek has a profound impact on appearance that is responsible for giving the 'tired' look we associate with aging.

The soft tissues of the mid-cheek are structurally composed of three segments or "modules", with each overlying a specific part of the mid-cheek skeleton (**Fig. 6.16**). The lid-cheek segment overlies the prominence of the inferior orbital rim, the malar segment overlies the body of the zygoma and the nasolabial segment overlies the anterior surface of the maxilla. The skeletal foundation of the mid-cheek borders the three bony cavities of the anterior face, the orbital, nasal and oral cavities. Because of the many spaces and limited bony support available, the mid-cheek has some intrinsic structural weaknesses. Three factors make the mid-cheek susceptible to aging changes. These are: (1) the wedge shape of the soft tissue of the mid-cheek, which are thin above and thicker below; (2) the natural posterior incline of the mid-cheek skeleton, from the relative prominence of the infra-orbital rim; and (3) the significant retrusion as a result of resorption of the maxilla with aging. This is not uniform, as the maxilla recedes more medially and inferiorly.⁵⁸⁻⁶¹ With early aging, the retrusion of the maxilla, along with a slight descent of the wedge shaped cheek soft tissue results in an appreciable reduction of volume of the upper cheek. The result is that the small amount of orbital fat over the prominent edge of the infra-orbital rim, (originally concealed by the volume of the upper

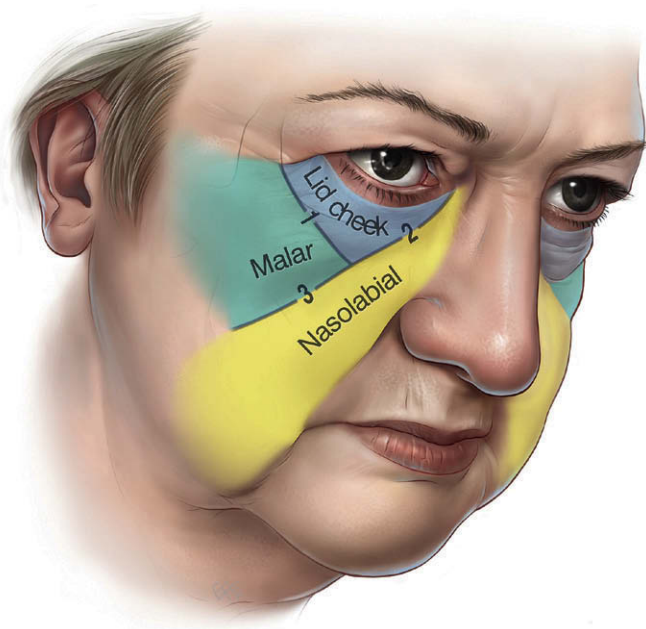


Fig. 6.16 The mid-cheek has three segments, the lid-cheek segment (blue) and the malar segment (green) are within the periorbital part and are adjacent to the nasolabial segment (yellow) in the perioral part, which overlies the vestibule of the oral cavity. The three grooves define the boundaries of the three segments and interconnect like the italic letter Y. The palpebromalar groove (1) overlies the inferomedial orbital rim and the nasojugal groove (2) which overlies the inferolateral orbital rim, then continues into the mid-cheek groove (3). (© Dr Levent Efe, CML.)

cheek), now becomes revealed, especially the underside of the lid fat bulge over the middle part. The visual impression is of a 'lengthened' lower lid.⁴⁷ At the same time, the increased thickness of the soft tissue mass over the lower cheek tends to conceal the degree of maxillary resorption and gives the profound visual impression that the soft tissue mass has descended into the lower part of the mid-cheek.

Of the three segments of the mid-cheek, the lower lid segment changes the most dynamically with aging. It has two distinct grooves across its surface, which vary in their expression during the aging process, often co-existing. The upper is the infratarsal groove at the junction of the pretarsal and preseptal parts of the eyelid. The groove is defined by the lower boundary of the pretarsal muscle bulge. The pretarsal bulge in youth is the visual separation of the lid above and the cheek below. This so-called "high lid-cheek junction" is located well above the infraorbital rim and is a characteristic of youth. The infratarsal groove location does not change with aging, although its contour usually fades. The lower groove is the lid-cheek junction that relates to the lower edge of the preseptal part of the lid. It is not usually present in youth and appears with aging and then progressively deepens and descends slightly over time. Its shape when it first appears is a gentle C contour but as it "descends", particularly in its central portion, its shape changes to a progressively more angulated V shape with the medial side being formed by the developing nasojugal groove and the lateral side by the palpebromalar groove. The center of the V, the lowest and deepest part has the nasojugal groove continuing down the cheek as the mid cheek groove that separates the cheek into the malar and nasolabial segments. The reason why this contour demarcation changes while the skin itself does not descend is

explained by difference in the tissue layers. In level 4, the orbicularis retaining ligament is not rigid where it is over the center of the inferior orbital rim, so distension results in relative sliding between it and layer 3, the orbicularis oculi. As the lid-cheek junction becomes more prominent, it visually takes over from the infratarsal groove and becomes the new separation between the lower eyelid and the cheek. This is the basis for the commonly used but misleading phrase "lengthening of the lid cheek junction with aging", which is in fact the result of a visual shift from the prominence of the infratarsal groove in youth to the lid-cheek junction with age. Correction of the aging of the lid cheek segment of the mid-cheek, the visibly descended contour of the lid cheek junction and long lower lid, has gained the colloquial name of "blending the lid cheek junction."

Lower face

The jowl and the labiomandibular fold in the lower face are not present in youth, and develop with aging. With the description of the concept of soft tissue spaces of the face, and specifically the premasseter space, the mechanism for the formation of the jowl can now be understood on an anatomical basis.⁶⁸ With the onset of aging, laxity develops in the roof of the premasseter space associated with attenuation of the anterior and inferior boundaries. The major retaining ligaments (the key masseteric and mandibular) in contrast remain relatively strong and at these locations the superficial fascia remains firmly fixed to the underlying deep fascia. Distension of the weaker masseteric ligaments at the anterior border of the lower premasseter space (below the key masseteric ligament) and inferior displacement of the buccal fat (within the buccal space) is the anatomical basis for the development of the labiomandibular fold. The mandibular ligament demarcates the transition from the labiomandibular fold above and the jowl below. The jowl develops as a result of distension of the roof of the lower premasseter space with resultant descent of the tissues below the body of the mandible. The more prominent the jowl, the more apparent will be the cutaneous tethering provided by the mandibular ligament. Accordingly, the anatomical solution to correcting these aging changes is to reduce the inferiorly displaced buccal fat and to tighten the roof of the premasseter space.

Considerations for correcting aging changes of the face based on the anatomy of the aging face

Dissection planes

The subcutaneous plane of dissection (*level 2*) is the most commonly used plane in facelifts, either in isolation or more commonly with some form of SMAS management from the superficial aspect (*Fig. 6.17*).^{69–71} A distinction should be drawn between subcutaneous dissection over the lateral face from that over the anterior face. This plane of dissection is perceived to be "safe" as dissection remains superficial to the facial nerve branches at all times and is the main appeal of level 2 dissection. The subcutaneous dissection can be

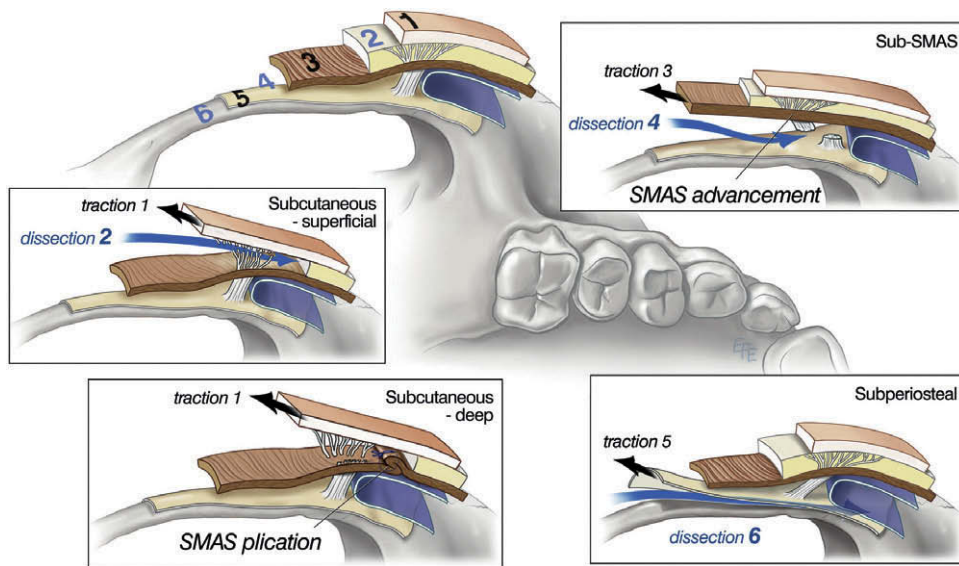


Fig. 6.17 Alternative levels for dissection and redraping in facelifts. Dissection can be performed through any one of three alternative layers, namely subcutaneous (level 2), subSMAS (level 4) and subperiosteal for the upper two-thirds of the face. (© Dr Levent Efe, CMI.)

performed either in the superficial subcutaneous or deep subcutaneous level. In the former, there is more density of the reticular cutis fibres as the multi-linked ligaments branches out before inserting into the dermis. In the latter on the outer surface of the SMAS, there are fewer fibres, which tend to be thicker and stronger. The deep subcutaneous layer is not uniform in its tenacity: some areas, as over the facial spaces are inherently easier to dissect, while others that overlie the ligament are more adherent and require sharp release.^{7,72} For example, over the malar eminence at McGregor's patch, where the zygomatic ligaments are located, sharp release is often needed as is required over the mandibular ligament. In contrast, in the lower face over the premasseter space, the subcutaneous layer separates quite readily, requiring only blunt finger dissection.

SubSMAS dissection (*level 4*): in the scalp, this is the preferred tissue plane for dissection as the scalp readily separates from the underlying periosteum (*level 5*) through the avascular areolar tissue with ease and inherent safety. Bruising and swelling is kept to a minimum because of this anatomy. In the face proper, while the anatomical principles remain the same, level 4 is potentially the most risky plane to dissect because of the facial nerve branches which transition through this level, from level 5, to supply the facial muscles in level 3. However, it should be noted that similar to the situation in the scalp where raising the flap at level 4 gives a robust and structurally integrated composite flap that can be effectively tightened, subSMAS dissection in the face has the same advantages and potential benefits.^{73,74} Dissection can be performed safely in level 4 by applying the understanding of the three-dimensional anatomy of the face described earlier; the key being the facial spaces, which provide safe access through this layer. Because these spaces are 'pre-dissected', access is quick, atraumatic, and easy. An example of this is the lower premasseter space. Subcutaneous dissection is performed to approximately 30 mm anterior to the tragus through the zone of fixation, the platysma auricular fascia (PAF), where the SMAS is fused to the deep fascia including the parotid capsule. Because the objective of the surgery is to correct laxity in the mobile anterior face, the level of dissection used in the lateral face is of secondary importance. A further benefit of leaving

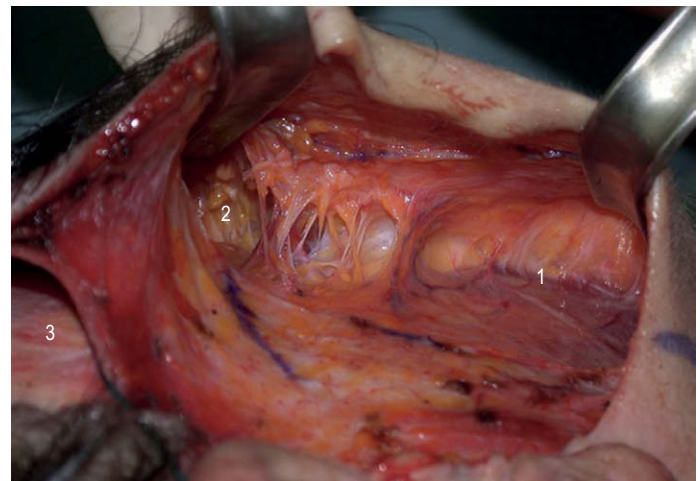


Fig. 6.18 Using the facial spaces for safe and anatomical access to subSMAS dissection in facelifts. (1) Premasseter space. (2) Prezygomatic space. (3) Upper temporal space.

the PAF intact is that it is strong and can be used for suture fixation.⁷⁵ Once dissection has proceeded beyond the PAF (indicated by the posterior border of the platysma), the SMAS should then be incised to gain direct access into the lower premasseter space. The space can then be opened by gentle blunt dissection only, to define the boundaries of the space. The premasseter space below and the prezygomatic space above form a series of spaces in the anterior face (**Fig. 6.18**). The boundaries of the spaces, reinforced by retaining ligaments, are where the important anatomy is located. These need to be precisely released to eliminate their tethering effect on the soft tissues,⁷⁶ which is more difficult in younger patients as the ligaments are denser and stronger. Clear visualization, optimized by lifting the opened adjacent facial spaces, is beneficial. When blunt scissors are used with gentle vertical spreading of the blades the surrounding fat and areolar tissue separate to reveal the ligaments and the facial nerve branches in relation to them. With further lifting, the ligaments become more certainly defined as they tighten further, at which time they can be safely released while the nerves, being obliquely

orientated, dislodge out of the way, unaffected by the controlled stretching. The subSMAS spaces can be used to safely and atraumatically access various part of the face, the deep temporal space to the lateral brow,¹³ the preseptal space to the lower eyelid, and the prezygomatic space to the mid-cheek.^{15,16}

Level 5: subperiosteal “lifts” have the appeal of safety as far as the facial nerve risk is concerned as they are superficial and the remote nerves never cross this plane.⁷⁷⁻⁷⁹ However, there are inherent limitations to subperiosteal lifts. The accumulated aging changes across all five layers are elevated as part of the subperiosteal lift. Overcorrection is required to effect the desired changes of soft tissue shape and skin tone, to compensate for the “lift-lag” phenomenon, which is in proportion to the soft tissue thickness and laxity. Accordingly, subperiosteal lifts work best in areas where the layers are more compacted as the lift-lag is minimized. An example being in the brow where subperiosteal lifts are effective and popular.⁸⁰ Where the layers are thicker, such as the nasolabial segment of the mid-cheek, the lift-lag phenomenon significantly limits the improvement that can be achieved. Because of the unyielding nature of the periosteum, extensive undermining beyond the target area is needed or alternatively a “periosteal release” immediately beyond the area that requires lifting to isolate the area to a limited island of periosteum

Placement of sutures

While adequate surgical release is needed for mobility, it is the surgical fixation that achieves the desired effect by holding the mobilized soft tissue in its new position.⁷⁶ The strength

and tenacity of the superficial fascia is not uniform. The areas where the retaining ligaments are located have inherent ligamentous reinforcement, making them ideal for suture placement. It is also the location in which traction gives the most natural appearance, as these are the natural suspension sites of the face. Accordingly, the suture fixation should be placed where the retaining ligaments are located. Where fixation sutures are placed in the anterior face in subSMAS surgery, they function as replacements for the retaining ligaments that have weakened or have been divided in order to mobilize the composite flap. Accordingly, the replacement sutures should replicate the quality of support provided by the original ligaments as the “mobile” spaces remain. In this respect braided permanent sutures are advantageous as they stimulate collagen and elastic deposition within the suture similar to a ligament.⁸¹ The platysma auricular fascia, a diffuse ligamentous area on the lateral face, provides an ideal area both anatomically and physically to fix the facelift flap, due to its inherent strength.

Summary

This chapter has been structured to assist the reader to develop a conceptual understanding of facial anatomy and how it changes with aging. It is the framework that unifies the detailed anatomical information now available in the literature. Once understood, this knowledge provides the anatomical foundation for the logical and sound selection of surgical techniques for rejuvenation of the aging face.



Access the complete references list online at <http://www.expertconsult.com>

4. Mendelson BC, Jacobson SR. Surgical anatomy of the mid-cheek; facial layers, spaces, and mid-cheek segments. *Clin Plast Surg*. 2008;35:395–404.
5. Stuzin JM, Baker TJ, Gordon HL. The relationship of the superficial and deep facial fascias: relevance to rhytidectomy and aging. *Plast Reconstr Surg*. 1992;89(3):441–449.
A discussion of the concept of facial soft tissue being arranged in concentric layers, and the SMAS as the “investing” layer of the superficial mimetic muscles of the face. The relationship between the deep and superficial fascias is described, with acknowledgement of “areola” planes and areas of dense fibrous attachments, including true osteocutaneous ligaments and other coalescences representing the retaining ligamentous boundaries of the face. Age-associated laxity of the retaining ligament was noted to be a key component of facial aging.
7. Furnas DW. The retaining ligaments of the cheek. *Plast Reconstr Surg*. 1989;83:11.
10. Rohrich RJ, Pessa JE. The fat compartments of the face: anatomy and clinical implications for cosmetic surgery. *Plast Reconstr Surg*. 2007;119(7):2219–2227.
13. Muzaffar AR, Mendelson BC, Adams WP Jr. Surgical anatomy of the ligamentous attachments of the lower lid and lateral canthus. *Plast Reconstr Surg*. 2002;110(3):873–884.
14. Moss CJ, Mendelson BC, Taylor GI. Surgical anatomy of the ligamentous attachments in the temple and periorbital regions. *Plast Reconstr Surg*. 2000;105(4):1475–1490.
A thorough description of the retaining ligaments of the temporal and periorbital regions is given. The term “ligamentous adhesion” is introduced to increase the understanding of the system, and there is emphasis on the relations of the temporal branch of the facial nerve and the trigeminal branches to structures visualized in surgery rather than to less useful landmarks which are not. A discussion of age related changes to the region compliments one of surgical approach with respect to the anatomy described.
16. Mendelson BC, Muzaffar AR, Adams WP Jr. Surgical anatomy of the mid-cheek and malar mounds. *Plast Reconstr Surg*. 2002;110(3):885–911.
18. Knize DM. Anatomic concepts for brow lift procedures. *Plast Reconstr Surg*. 2009;124(6):2118–2126.
68. Mendelson BC, Freeman ME, Wu W, et al. Surgical anatomy of the lower face: the premasseter space, the jowl, and the labiomandibular fold. *Aesthetic Plast Surg*. 2008;32 (2):185–195.
Introduces the concept of the “premasseter” space, age-related changes, and utility for safe subSMAS dissection. Distinction is made between this space,

over the lower part of the masseter, and another space overlying the upper part of the masseter where the neurovascular structures, the accessory lobe of the parotid gland and duct are located. The true shape of the anterior border of the masseter muscle is described, with the border ending anteroinferiorly at the mandibular ligament. This description completes the picture of the retaining ligaments as a continuous border separating the anterior and lateral parts of the face. The relations of the facial nerve branches, particularly that of the lower buccal trunk, to the masseter and its fascia is described.

75. Mendelson BC. Surgery of the superficial musculoaponeurotic system: principles of release, vectors and fixation. *Plast Reconstr Surg.* 2001;107(6): 1545–1552.

This article highlights the importance of adequate release of retaining ligaments of the SMAS in repositioning of the composite flap. Inadequate release can lead to suboptimal advancement of the flap, and worse, distortion of the flap if the direction of pull is incorrect, due to unwanted rotation about the parts of the retaining ligamentous system which have been left intact. The biomechanical function of the retaining ligaments is described as “quarantining” sections of the SMAS with less substantial fixation (areas now appreciated as subSMAS facial soft tissue spaces), preventing unwanted traction on areas of the face distant to the desired action in facial expression. There is discussion on the advantage of extensive SMAS mobilization in allowing multiple and varied force vectors to be applied, which allows proper anatomical repositioning of the soft tissue of the face.

References

- Mendelson BC. Facelift anatomy, SMAS, retaining ligaments and facial spaces. In: Aston J, Steinbrech DS, Walden JL, eds. *Aesthetic plastic surgery*. London: Saunders Elsevier; 2009:53–72.
- Nahai F, ed. Clinical decision making in face lift and neck lift. In: *The art of aesthetic surgery: principles and techniques*. St Louis: Quality Medical; 2005:898–926.
- Mendelson BC. Correction of the nasolabial fold: extended SMAS dissection with periosteal fixation. *Plast Reconstr Surg*. 1992;89(5):822–833.
- Mendelson BC, Jacobson SR. Surgical anatomy of the mid-cheek; facial layers, spaces, and mid-cheek segments. *Clin Plast Surg*. 2008;35:395–404.
- Stuzin JM, Baker TJ, Gordon HL. The relationship of the superficial and deep facial fascias: relevance to rhytidectomy and aging. *Plast Reconstr Surg*. 1992;89(3):441–449.
A discussion of the concept of facial soft tissue being arranged in concentric layers, and the SMAS as the “investing” layer of the superficial mimetic muscles of the face. The relationship between the deep and superficial fascias is described, with acknowledgement of “areola” planes and areas of dense fibrous attachments, including true osteocutaneous ligaments and other coalescences representing the retaining ligamentous boundaries of the face. Age-associated laxity of the retaining ligament was noted to be a key component of facial aging.
- Mendelson BC. Advances in the understanding of the surgical anatomy of the face. In: Eisenmann-Klein M, Neuhaun-Lorenz C, eds. *Innovations in plastic and aesthetic surgery*. New York: Springer Verlag; 2007:141–145.
- Furnas DW. The retaining ligaments of the cheek. *Plast Reconstr Surg*. 1989;83:11.
- Furnas D. The superficial musculoaponeurotic plane and the retaining ligaments of the face. In: Psillakis JM, ed. *Deep face-lifting techniques*. New York: Thieme Medical; 1994.
- Rohrich RJ, Pessa JE. The retaining system of the face: histologic evaluation of the septal boundaries of the subcutaneous fat compartments. *Plast Reconstr Surg*. 2008;121(5):1804–1809.
- Rohrich RJ, Pessa JE. The fat compartments of the face: anatomy and clinical implications for cosmetic surgery. *Plast Reconstr Surg*. 2007;119(7):2219–2227.
- Rohrich RJ, Pessa JE. The anatomy and clinical implications of perioral submuscular fat. *Plast Reconstr Surg*. 2009;124(1):266–271.
- Mitz V, Peyronie M. The superficial musculoaponeurotic system (SMAS) in the parotid and cheek area. *Plast Reconstr Surg*. 1976;58:80.
- Muzaffar AR, Mendelson BC, Adams WP Jr. Surgical anatomy of the ligamentous attachments of the lower lid and lateral canthus. *Plast Reconstr Surg*. 2002;110(3):873–884.
- Moss CJ, Mendelson BC, Taylor GI. Surgical anatomy of the ligamentous attachments in the temple and periorbital regions. *Plast Reconstr Surg*. 2000;105(4):1475–1490.
A thorough description of the retaining ligaments of the temporal and periorbital regions is given. The term “ligamentous adhesion” is introduced to increase the understanding of the system, and there is emphasis on the relations of the temporal branch of the facial nerve and the trigeminal branches to structures visualized in surgery rather than to less useful landmarks which are not. A discussion of age related changes to the region compliments one of surgical approach with respect to the anatomy described.
- Ghavami A, Pessa JE, Janis J, et al. The orbicularis retaining ligament of the medial orbit: closing the circle. *Plast Reconstr Surg*. 2008;121(3):994–1001.
- Mendelson BC, Muzaffar AR, Adams WP Jr. Surgical anatomy of the mid-cheek and malar mounds. *Plast Reconstr Surg*. 2002;110(3):885–911.
- Yousif NJ, Mendelson BC. Anatomy of the midface. *Clin Plast Surg*. 1995;22(2):227–240.
- Knize DM. Anatomic concepts for brow lift procedures. *Plast Reconstr Surg*. 2009;124(6):2118–2126.
- Kahn JL, Wolfram-Gabel R, Bourjat P. Anatomy and imaging of the deep fat of the face. *Clin Anat*. 2000;13(5):373–382.
- Zhang HM, Yan YP, Qi KM, et al. Anatomical structure of the buccal fat pad and its clinical adaptations. *Plast Reconstr Surg*. 2002;109(7):2509–2518.
- Baker DC, Conley J. Avoiding facial nerve injuries in rhytidectomy: anatomic variations and pitfalls. *Plast Reconstr Surg*. 1979;64:781.
- Gosain AK. Surgical anatomy of the facial nerve. *Clin Plast Surg*. 1995;22:241.
- Seckel BR. *Facial danger zones. Avoiding nerve injury in facial plastic surgery*. St Louis: Quality Medical; 1994.
- Owsley JQ, Agrawal CA. Safely navigating around the facial nerve in three-dimensions. *Clin Plast Surg*. 2008;35:469–477.
- Lowe JB 3rd, Cohen M, Hunter DA, et al. Analysis of the nerve branches to the orbicularis oculi muscle of the lower eyelid in fresh cadavers. *Plast Reconstr Surg*. 2005;116(6):1743–1749.
- Furnas DW. Landmarks for the trunks and the temporofacial division of the facial nerve. *Br J Surg*. 1965;52:694–696.
- Stuzin JM, Wagstrom L, Kawamoto HK, et al. Anatomy of the frontal branch of the facial nerve: the significance of the temporal fat pad. *Plast Reconstr Surg*. 1989;83(2):265–271.
- Ramirez OM, Maillard GF, Musolas A. The extended subperiosteal face lift: a definitive soft-tissue remodeling for facial rejuvenation. *Plast Reconstr Surg*. 1991;88(2):227–236.
- Trussler AP, Stephan P, Hatef D, et al. The frontal branch of the facial nerve across the zygomatic arch: anatomical relevance of the high-SMAS technique. *Plast Reconstr Surg*. 2010;125(4):1221–1229.
- Agarwal CA, Mendenhall SD 3rd, Foreman KB, et al. The course of the frontal branch of the facial nerve in

- relation to fascial planes: an anatomic study. *Plast Reconstr Surg*. 2010;125(2):532–537.
31. Montagna W, Carlisle K. Structural changes in the aging skin. *Br J Dermatol*. 1990;122(Suppl 35):61–70.
 32. Ramirez OM, Santamaria R. Spatial orientation of motor innervation of the lower orbicularis oculi muscle. *Aesthetic Surg J*. 2000;20:107.
 33. Ruess W, Owsley JQ. The anatomy of the skin and fascial layers of the face in aesthetic surgery. *Clin Plast Surg*. 1987;14(4):677–682.
 34. Byrd HS, Andochick SE. The deep temporal lift: a multiplanar, lateral brow, temporal, and upper face lift. *Plast Reconstr Surg*. 1996;97(5):928–937.
 35. Dingman RO, Grabb WC. Surgical anatomy of the mandibular ramus of the facial nerve based on the dissection of 100 facial halves. *Plast Reconstr Surg*. 1962;29:266.
 36. Conley J, Baker DC. Paralysis of the mandibular branch of the facial nerve. *Plast Reconstr Surg*. 1982;70:569.
 37. Nelson DW, Gingrass RP. Anatomy of the mandibular branches of the facial nerve. *Plast Reconstr Surg*. 1979; 63:479.
 38. Pitanguy I, Ramos AS. The frontal branch of the facial nerve: the importance of its variations in facelifting. *Plast Reconstr Surg*. 1966;38:352–356.
 39. Wulf HC, Sandby-Moller J, Kobayashi T, et al. Skin aging and natural photoprotection. *Micron*. 2004;35: 185–191.
 40. Hall G, Phillips TJ. Estrogen and skin: the effects of estrogen, menopause and hormone replacement therapy on the skin. *J Am Acad Dermatol*. 2005;53: 555–568.
 41. Sander CS, Chang H, Salzmann S, et al. Photoaging is associated with protein oxidation in human skin in vivo. *Invest Dermatol*. 2002;118(4):618–625.
 42. Chung JH, Seo JY, Choi HR, et al. Modulation of skin collagen metabolism in aged and photoaged human skin in vivo. *J Invest Dermatol*. 2001;117(5):1218–1224.
 43. Freiman A, Bird G, Metelitsa AI, et al. Cutaneous effects of smoking. *J Cutan Med Surg*. 2004;8(6):415–423.
 44. Gosain AK, Klein MH, Sudhakar PV, et al. A volumetric analysis of soft-tissue changes in the aging midface using high-resolution MRI: implications for facial rejuvenation. *Plast Reconstr Surg*. 2005;115(4):1143–1155.
 45. Gosain AK, Amarante MT, Hyde JS, et al. A dynamic analysis of changes in the nasolabial fold using magnetic resonance imaging: implications for facial rejuvenation and facial animation surgery. *Plast Reconstr Surg*. 1996;98(4):622–636.
 46. Lambros V. Observations on periorbital and midface aging. *Plast Reconstr Surg*. 2007;120(5):1367–1376.
 47. Faulkner JA, Larkin LM, Claflin DR, et al. Age-related changes in the structure and function of the skeletal muscles. *Clin Exp Pharmacol Physiol*. 2007;34:1091–1096.
 48. Pottier F, El-Shazly NZ, El-Shazly AE. Aging of orbicularis oculi: anatomophysiological consideration in upper blepharoplasty. *Arch Facial Plast Surg*. 2008;10(5): 346–349.
 49. Penna V, Stark GB, Eisenhardt SU, et al. The aging lip: a comparative histological analysis of age-related changes in the upper lip complex. *Plast Reconstr Surg*. 2009;124(2):624–628.
 50. Pessa JE, Zadoo VP, Yuan C, et al. Concertina effect and facial aging: nonlinear aspects of youthfulness and skeletal remodeling, and why, perhaps, infants have jowls. *Plast Reconstr Surg*. 1999;103(2):635–644.
 51. Schwartz GE, Fair PL, Mandel MR, et al. Facial electromyography in the assessment of improvement in depression. *Psychosom Med*. 1978;40:355.
 52. Hellman M. Changes in the human face brought about by development. *Int J Orthod*. 1927;13:475.
 53. Todd TW. Thickness of the white male cranium. *Anat Rec*. 1924;27:245.
 54. Lasker GW. The age factor in bodily measurements of adult male and female Mexicans. *Hum Biol*. 1953;25:50.
 55. Garn SM, Rohmann CG, Wagner B, et al. Continuing bone growth during adult life: A general phenomenon. *Am J Phys Anthropol*. 1967;26:313.
 56. Kahn DM, Shaw RB Jr. Aging of the bony orbit: a three-dimensional computed tomographic study. *Aesthet Surg J*. 2008;28(3):258–264.
 57. Pessa JE, Chen Y. Curve analysis of the aging orbital aperture. *Plast Reconstr Surg*. 2002;109(2):751–755.
 58. Pessa JE, Zadoo VP, Mutimer KL, et al. Relative maxillary retrusion as a natural consequence of aging: combining skeletal and soft-tissue changes into an integrated model of midfacial aging. *Plast Reconstr Surg*. 1998;102(1):205–212.
 59. Pessa JE. An algorithm of facial aging: verification of Lambros's theory by three-dimensional stereolithography, with reference to the pathogenesis of midfacial aging, scleral show, and the lateral suborbital trough deformity. *Plast Reconstr Surg*. 2000;106(2): 479–488.
 60. Shaw RB Jr, Kahn DM. Aging of the midface bony elements: a three-dimensional computed tomographic study. *Plast Reconstr Surg*. 2007;119(2):675–681.
 61. Mendelson BC, Hartley W, Scott M, et al. Age-related changes of the orbit and mid-cheek and the implications for facial rejuvenation. *Aesthetic Plast Surg*. 2007;31(5): 419–423.
 62. Zadoo VP, Pessa JE. Biological arches and changes to the curvilinear form of the aging maxilla. *Plast Reconstr Surg*. 2000;106(2):460–466.
 63. Pessa JE, Slice DE, Hanz KR, et al. Aging and the shape of the mandible. *Plast Reconstr Surg*. 2008;121(1): 196–200.
 64. Shaw RB Jr, Katzel EB, Koltz PF, et al. Aging of the mandible and its aesthetic implications. *Plast Reconstr Surg*. 2010;125(1):332–342.
 65. Knize DM. Muscles that act on glabella skin: A closer look. *Plast Reconstr Surg*. 2000;105:350.
 66. Matros E, Garcia JA, Yaremchuk MJ. Changes in eyebrow position and shape with aging. *Plast Reconstr Surg*. 2009;124(4):1296–1301.

67. Jelks GW, Jelks EB. The influence of orbital and eyelid anatomy on the palpebral aperture. *Clin Plast Surg.* 1991;18(1):183–195.
68. Mendelson BC, Freeman ME, Wu W, et al. Surgical anatomy of the lower face: the premasseter space, the jowl, and the labiomandibular fold. *Aesthetic Plast Surg.* 2008;32(2):185–195.
Introduces the concept of the “premasseter” space, age-related changes, and utility for safe subSMAS dissection. Distinction is made between this space, over the lower part of the masseter, and another space overlying the upper part of the masseter where the neurovascular structures, the accessory lobe of the parotid gland and duct are located. The true shape of the anterior border of the masseter muscle is described, with the border ending anteroinferiorly at the mandibular ligament. This description completes the picture of the retaining ligaments as a continuous border separating the anterior and lateral parts of the face. The relations of the facial nerve branches, particularly that of the lower buccal trunk, to the masseter and its fascia is described.
69. Baker DC. Lateral SMASectomy. *Plast Reconstr Surg.* 1997;100:509–513.
70. Tonnard P, Verpaele A. The MACS-lift short scar rhytidectomy. *Aesthet Surg J.* 2007;27(2):188–198.
71. Aston SJ, Walden JL. Facelift with SMAS techniques and FAME. In: Aston SJ, Steinbrech DS, Walden JL, eds. *Aesthetic plastic surgery.* London: Saunders Elsevier; 2009;73–86.
72. Labbé D, Franco RG, Nicolas J. Platysma suspension and platysmaplasty during neck lift: anatomical study and analysis of 30 cases. *Plast Reconstr Surg.* 2006;117(6):2001–2007.
73. Hamra ST. Deep-plane rhytidectomy. *Plast Reconstr Surg.* 1990;86:53.
74. Hamra ST. Composite rhytidectomy. *Plast Reconstr Surg.* 1992;90:1.
75. Mendelson BC. Surgery of the superficial musculoaponeurotic system: principles of release, vectors and fixation. *Plast Reconstr Surg.* 2001;107(6):1545–1552.
This article highlights the importance of adequate release of retaining ligaments of the SMAS in repositioning of the composite flap. Inadequate release can lead to suboptimal advancement of the flap, and worse, distortion of the flap if the direction of pull is incorrect, due to unwanted rotation about the parts of the retaining ligamentous system which have been left intact. The biomechanical function of the retaining ligaments is described as “quarantining” sections of the SMAS with less substantial fixation (areas now appreciated as subSMAS facial soft tissue spaces), preventing unwanted traction on areas of the face distant to the desired action in facial expression. There is discussion on the advantage of extensive SMAS mobilization in allowing multiple and varied force vectors to be applied, which allows proper anatomical repositioning of the soft tissue of the face.
76. Le Louarn C. The concentric malar lift: malar and lower eyelid rejuvenation. *Aesthetic Plast Surg.* 2004;28(6):359–372.
77. Sullivan SA, Dailey RA. Endoscopic subperiosteal midface lift: surgical technique with indications and outcomes. *Ophthal Plast Reconstr Surg.* 2002;18(5):319–330.
78. Ramirez OM. Three-dimensional endoscopic midface enhancement: a personal quest for the ideal cheek rejuvenation. *Plast Reconstr Surg.* 2002;109(1):329–340.
79. Rowe DJ, Guyuron B. Optimizing results in endoscopic forehead rejuvenation. *Clin Plast Surg.* 2008;35(3):355–360.
80. Huggins RJ, Freeman ME, Kerr JB, et al. Histologic and ultrastructural evaluation of sutures used for surgical fixation of the SMAS. *Aesthetic Plast Surg.* 2007;31(6):719–724.
81. Freilinger G, Gruber H, Happat W, et al. Surgical anatomy of the mimic muscle system and the facial nerve: Importance for reconstructive and aesthetic surgery. *Plast Reconstr Surg.* 1987;80:686.