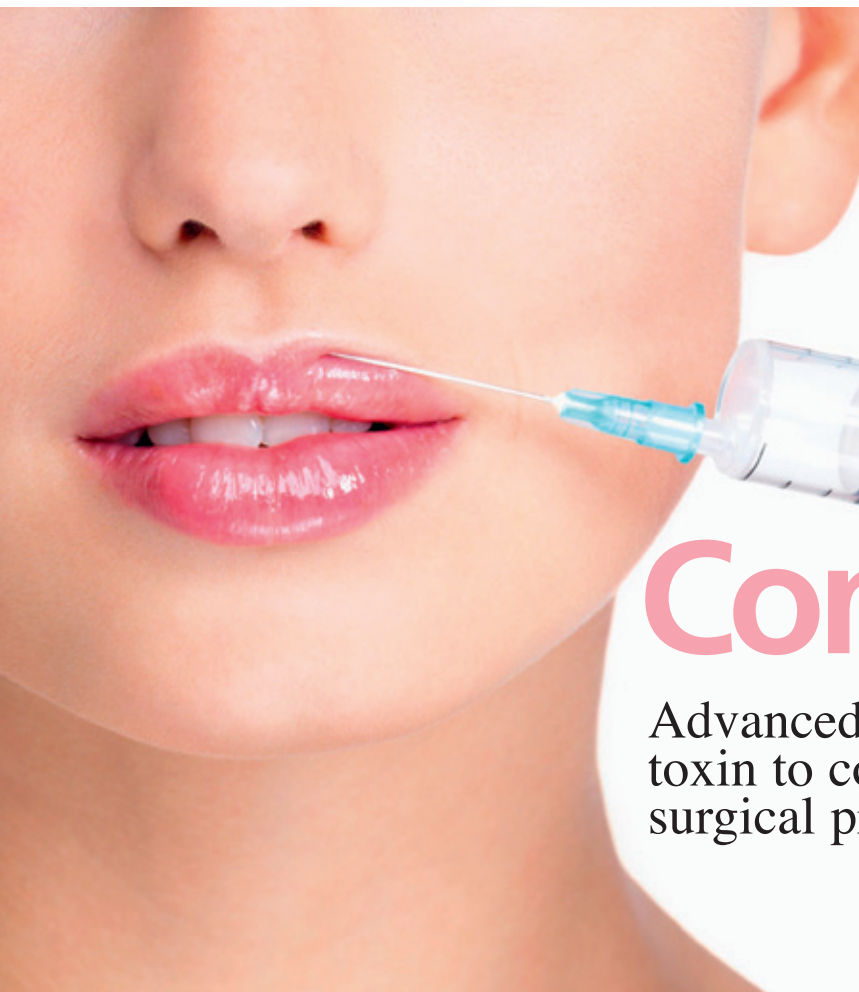



Botox Complement

by Dr Wong Chin Ho

Advanced applications of botulinum toxin to complement fillers and surgical procedures on the face



Dr Wong Chin Ho is a Plastic Surgeon practicing at Mount Elizabeth Novena Specialist Centre. He is currently the Director of W aesthetic Plastic Surgery. He did a one-year Reconstructive Microsurgery and

Aesthetic Surgery fellowship in 2007 under Professor Fu-Chan Wei at the Chang Gung Memorial Hospital in Taiwan. This was followed by a six-month Advanced Facial Aesthetic Fellowship with Dr Bryan Mendelson in Melbourne Australia in 2009. In 2010 he was awarded the first International Fellowship by the American Society of Aesthetic Surgery (ASAPS). This scholarship gave him the opportunity to spend time with and learn from top American plastic surgeons throughout the USA. This extensive experience and training gave him the skills to apply the most advanced techniques in Aesthetic Surgery for his patients.

He is active in research and has published over 60 peer review articles and contributed to several key reference textbooks in plastic surgery.

Botulinum toxin is a powerful neurotoxin that temporarily denervates neuromuscular transmission for about six months. Currently it is FDA-approved for the treatment of glabella frown lines for cosmetic purposes. All other cosmetic applications are currently considered off label use. Clinically, the use of botox in the face has a very good safety record with several million treatments done a year worldwide.

In my preceding article in this magazine (MG October 2012 issue), I talked about the use of Botox alone for cosmetic enhancement. The purpose of this article is to discuss the more advance application of botox to complement the use of fillers and surgery on the face. The benefit and potential of these applications are presented in the following illustrative cases.

Case Illustrations

The patient in [Figure 1] (left side, pretreatment), shows a patient presenting with the complaints of looking tired and fine wrinkling of the lower eyelid skin. To address these problems, a combination botox and fillers were needed. Microbotox of 6U on each of the lower eyelid was used to relax the superficial fibers of the orbicularis oculi to relieve the fine lower eyelid from wrinkling. As well as, 1cc of hyaluronic acid was used in each of the midcheek to correct her tear trough deformity. Seen after three weeks [Figure 1] (right side), her tired look has been effectively eliminated. She looked fresh with correction of the tear trough deformity as well as elimination of the fine wrinkling of the lower eyelid skin. The very low dose of botox used as well as the diffuse area injected, will only relax the superficial fibers of the orbicularis

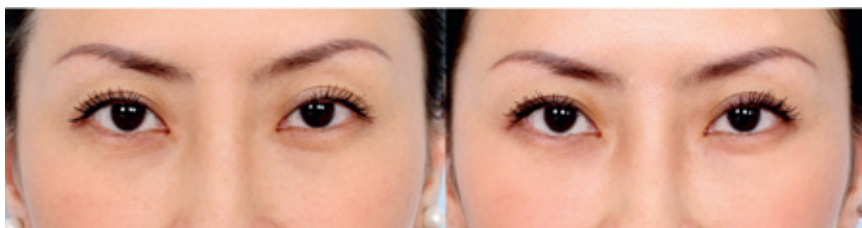

Figure 1

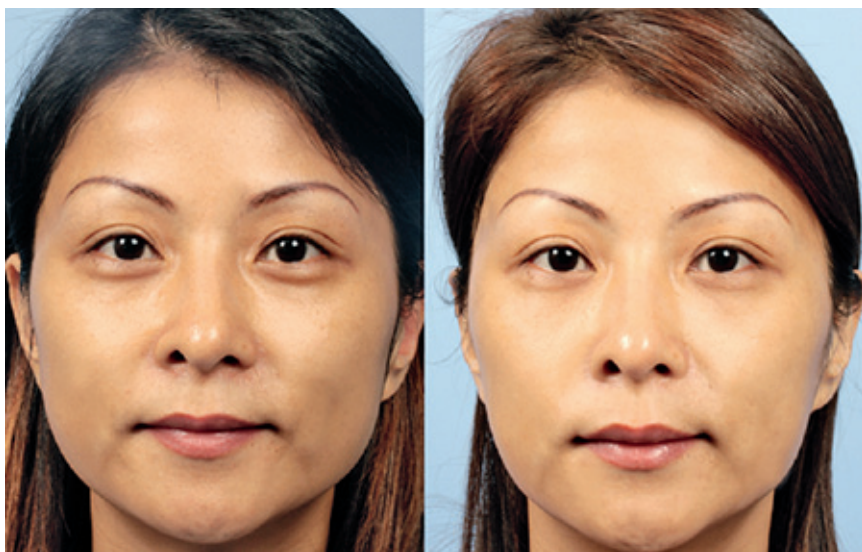

Figure 2

oculi, relaxing the fine wrinkling while animation (involving the deeper fibers) remained unaffected.

The patient in **[Figure 2]** (left side, pretreatment), shows a patient presenting with fine wrinkling of the lower eyelid skin, tear trough deformity, as well as a wide jawline.

To address these concerns, 6U of Microbotox was injected diffusely into the lower eyelid skin, 25U of botox was injected into each masseter and 0.5cc of hyaluronic acid was injected into each tear trough. Seen at two months after the treatment **[Figure 2]** (right side), her lower eyelid fine wrinkles was eliminated, her tear trough deformity has been corrected with a very fresh appearance compared with her preoperative appearance. Her jawline was also profoundly contoured from the treatment of her masseteric hypertrophy. The sharper jawline gives the profound visual impression of significant weight loss, the so called facial slimming jabs.

The patient in **[Figure 3]** (left side pretreatment) presented with complaints of obstruction of the upper part of her visual fields that were affecting her work. On examination, she has severe blepharospasm as well as dermatochalasia. Because of the severe blepharospasm however, the degree of the skin hooding as well as any associated ptosis were difficult to accurately determine. Surgery alone would not be effective in addressing her problems as the blepharospasm would continue to cause obstruction of her visual field. She was treated with 40U of Botox on each of the orbicularis oculi muscle circumferentially. One week after the botox, the periorbital area was completely relaxed and the degree of the ptosis can then be accurately assessed. She had 2mm of ptosis bilaterally with good levator function. An upper eyelid blepharoplasty with 8mm levator advancement on the right and

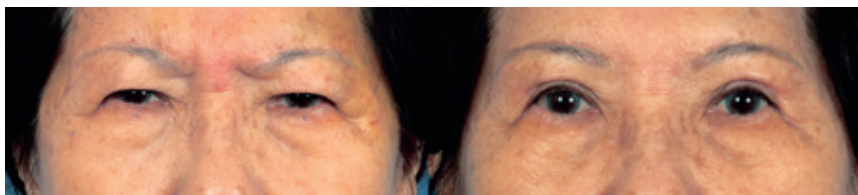


Figure 3

10mm on the left was performed. Seen at six months post operatively **[Figure 3]** (right side), she was seeing well and very pleased with the aesthetic outcome.

Botox is very safe and effective when correctly used. The more advanced applications of the medicine enhance the results that can be achieved with filler or even surgery alone. Combining these modalities predictably takes the cosmetic result attainable to the next level. **MG**

Reference

Carruthers J, Carruthers A. Botulinum toxin in facial rejuvenation: an update. *Dermatol Clin.* 2009 Oct;27(4):417-25, v.